

# Unilateral Ectopic Kidney with Associated Anomalies: A Case Report

Bashir Khan<sup>1\*</sup>, Bipin Khade<sup>2</sup>, Gajanan Patil<sup>3</sup>

<sup>1, 2, 3</sup>Assistant Professor, Department of Anatomy, Shri. Bhausaheb Hire Government Medical College, Dhule, Maharashtra, INDIA.

\*Corresponding Address:

[drbashirkhan@gmail.com](mailto:drbashirkhan@gmail.com)

## Case Report

**Abstract:** Present study is a case observed in the department of anatomy at Shri Bhausaheb Hire Government Medical College, Dhule. During routine cadaveric dissection of first M.B.B.S students in department of anatomy, a case of unilateral ectopic kidney with non rotation and vascular anomaly was found in an adult male cadaver. An accessory artery to inferior pole may obstruct the ureter leading to hydronephrosis. During operative procedures, a surgeon should be careful about accessory renal arteries because these are end arteries, consequently, if an accessory artery is damaged or ligated, the part of kidney supplied by it will become ischemic.

**Keywords:** Ectopic kidney, Non rotation, Vascular anomalies, Congenital anomalies.

## Introduction

The metanephros, which differentiates to form definitive kidney in human, is originally at the level upper sacral segments and receives its early arterial supply from lateral sacral branches of aorta. During its development, however, it undergoes a relative change of position, usually called 'ascent' of kidney. This ascent of kidney from its original pelvic to final lumbar position takes place between end of fifth week to eighth week. The ascent is usually due to rapid longitudinal growth of lumbar sacral segments and decrease in lumbar flexion of embryo. The kidney also undergoes a rotation so that the hilum which was originally on its ventral aspect comes to be situated on medial aspect. During ascent of kidneys their intrinsic blood vessels receive their blood supply from lateral stem arteries which arise from aorta at increasing higher levels until that of the definitive renal arteries, at the second lumbar vertebra, is reached. Persistence of blood supply from lower levels than normal gives rise to aberrant (accessory) renal arteries. Failure of ascent of kidney results in a congenital pelvic kidney[1]. An accessory artery to inferior pole (polar renal artery) may cross anterior to ureter and obstruct it, causing hydronephrosis – distension of renal pelvis and calices with urine. It is important to be aware that the accessory renal arteries are end arteries, consequently, if an accessory artery is damaged or ligated, the part of kidney supplied by it will become ischemic[2].

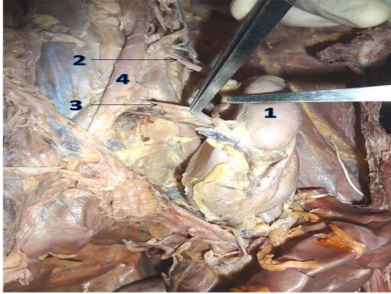
## Case Report

During routine cadaveric dissection of first M.B.B.S students in department of anatomy, Shri Bhausaheb Hire Government Medical College, Dhule, a case of unilateral ectopic kidney with non rotation and vascular anomaly was found in an adult formalin fixed male cadaver. When the abdomen was opened by classical incisions, the left kidney was observed at the level of pelvic brim opposite left sacroiliac joint. It was oval shaped with its pelvis facing anteriorly. It measured 9.5 cms vertically, 5 cms transversely and 3 cms in thickness. Weight of the kidney was 140 gms. The upper pole was more pointed than the lower pole. The ventral surface was characteristically marked by a large hilum occupied by dilated pelvis, two renal arteries and single renal vein. Its dorsal surface was smooth.



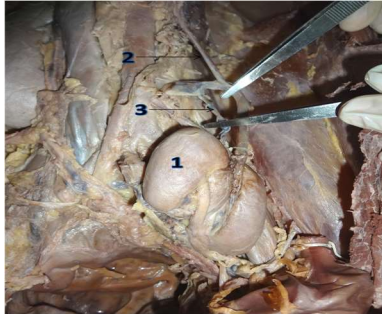
**Figure 1:** Photograph showing Right kidney [1], Left kidney [2], Left Ureter [3], Abdominal Aorta [4] and inferior vena cava [5]

There were two renal arteries supplying to left kidney. One larger and proximal renal artery arose from abdominal aorta 6 cms proximal its bifurcation and it entered the hilum of kidney from left side. One more smaller and distal renal artery was arising from right common iliac artery. It entered the substance of kidney through right side of hilum.



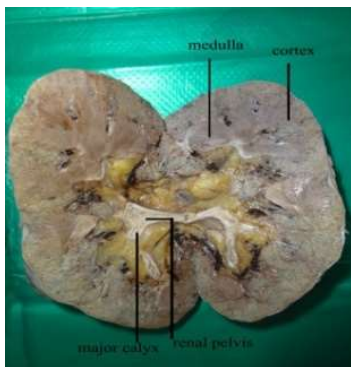
**Figure 2:** Photograph showing Left kidney [1] Proximal renal artery [2], Distal renal artery [3] and Abdominal Aorta [4]

There was single left renal vein draining the kidney which runs posterior to the aorta to open into the inferior vena cava. Left gonadal vein was draining in left renal vein.



**Figure 3:** Photograph showing Left kidney [1] Left renal vein [2] and left gonadal vein [3]

The left suprarenal gland situated in front of the left crus of diaphragm, opposite the vertebral end of the 11th and the 12th ribs. It received arterial supply from superior suprarenal artery, arising from the inferior phrenic artery, middle suprarenal artery and inferior suprarenal arteries were arising from the abdominal aorta. Cut section revealed normal cortex, medulla, renal pyramids, minor and major calyces, no cyst was observed. Paraffin sections were taken to observe histological differentiation of kidney. Slides were stained by Haematoxylin and eosin stain. Kidney showed normal mature histological development. The right kidney was found in the lumbar region with normal morphology.



**Figure 4:** Photograph showing Cortex, Medulla, Renal pelvis and Major calyces in cut section of left kidney

## Discussion

Developmentally the permanent kidney first lies in the pelvic cavity with its hilum directed anteriorly then the kidney gradually ascends with medial rotation and reaches the lumbar region with its hilum directed medially. The ascent of the kidney is caused by diminution of body curvature and by growth of the body in the lumbar and sacral regions. The ectopic position of kidney is due to arrest of its ascent during the development[3]. In congenital anomalies of all the systems, the urinary tract system anomalies accounts for 3.0%, in which the pelvic kidney is a rare anomaly about 1:2500 live births and the left kidney being more commonly affected. 2,3 Incidence of ectopic kidney has a reported frequency of 1:500 to 1:1100; ectopic thoracic kidney 1:13000; one normal and one pelvic kidney 1:3000 and crossed renal ectopic 1: 7000[4]. Gross abnormalities of kidney or ureter occur in at least 3% to 4% of persons. Among the most common abnormalities of position of kidneys is abnormal rotation[5]. Ectopic kidney is found in approximately 1 in 1000 births, but only 1 in 10 of these are ever diagnosed[6]. 5 The majority of thoracic ectopic kidney cases present as an intrathoracic tumor seen on chest X-rays ordered for reasons other than suspicion of this anomaly and do not require special treatment[7]. With growth, the kidneys gradually ascend to the abdomen and away from the midline. Since under-ascent is more common than over-ascent, ectopic kidneys are more commonly found in the pelvis or lower abdomen. Most renal anomalies are incidental findings[8]. The incidence of renal ectopia in postmortem studies varies from 1 in 500 to 1 in 1290. It occurs slightly more frequently on the left side and 10% of cases are bilateral. The male to female ratio is equal. Around 50% remain unrecognized throughout life. In parts of Kenya there is a 3 times increased incidence in unrelated subjects, suggesting an as yet another undefined environmental factor [9],[10],[11]. Muhammad Asghar and Fidaullah Wazir investigated 12,000 patients with plain radiography and ultrasonography. There were 25 (0.2%) cases of renal ectopia. Seven were having right ectopic pelvic, 5 left ectopic pelvic, 5 crossed ectopic fused, 2 crossed ectopic un-fused, 4 horseshoe shaped and 2 bilateral ectopic pelvic kidneys[12]. Pelvic ectopia is seen in an estimated 1 of 2100 to 3000 autopsies. Most ectopic kidneys are clinically asymptomatic and they are not more susceptible to disease than normally positioned kidneys, except for the development of hydronephrosis and urinary calculus formation[13]. The commonest cause of the failure of ascent is the presence of sickle-shaped peritoneal fold which projects from the lateral pelvic wall containing the umbilical artery[14]. Factors that may prevent orderly movement of the kidneys

include ureteral bud maldevelopment, defective metanephric tissue, genetic abnormalities, maternal illness and teratogenic causes. Although a simple ectopic kidney is seldom responsible for symptoms, the association with malrotation of the renal pelvis with a calculus increases the risk of hematuria, hydronephrosis, and stone formation with colicky pain, as in the present case[15,16]. The abnormal position of ectopic kidneys may result in a pattern of direct and referred pain that is atypical for colic and may be misdiagnosed as acute appendicitis or pelvic organ inflammatory disease in women. Other signs and symptoms of ectopic kidneys include incontinence, a palpable abdominal mass, urinary tract infection, renovascular hypertension secondary to an anomalous blood supply and dystocia from a pelvic kidney[17].

An ectopic kidney is often associated with an increased incidence of stone formation as a result of stasis caused by the altered geometry of urinary drainage[18]. Abbas Fadaii *et al* reported a case of a 72-year-old woman who suffered from nonspecific chest pain for 3 years. Chest radiography revealed a left posterior mediastinal mass which was later confirmed by chest computed tomography to be a congenital intrathoracic kidney[19]. The functional ectopic kidney may go undetected in life and may be observed only after death, either in autopsy or during dissection. Symptoms due to ectopic kidney may vary from none to pain, hydronephrosis, and pyelonephritis, renosigmoid fistulae or Lithiasis[20].

Renal ectopia may present diagnostic problems when acute renal disease develops and there is always a danger that an unwary surgeon may be tempted to remove it as an unexplained pelvic mass[21]. Multidetector computed tomographic (MDCT) urography enables a comprehensive evaluation of patients with renal fusion anomalies in a single examination. Especially three-dimensional reformatted images can provide good delineation of congenital fusion anomalies of the kidney[22]. Reddy *et al* reported a case of left ectopic kidney with non rotation and morphologically normal right kidney during routine dissection in adult male cadaver[23]. Blood supply to the ectopic kidney most frequently arises from the vessels on the ipsilateral side but occasionally arises from the contralateral side. Both the normally located kidney and its fused mate commonly have aberrant arterial anatomy; the arterial supply is from the upper abdominal aorta in 25% of cases and from the lower aorta or iliac arteries in the remainder. While the total number of arteries ranges from one to six, most commonly there are two to four major arteries to the two kidneys [24],[ 25]. In ectopia, the vascularization pattern remains frozen at whatever development stage the ascent ceases[26]. Renal artery variations are categorized in 2

groups: "early branching" and "extra renal arteries". While main renal arteries divide into segmental branches at hilus level, a branching occurring more proximal to hilus, is called "early branching". Extra renal arteries are grouped in 2 as follows: hilar (accessory) and polar (aberrant) arteries. While hilar arteries enter kidney through hilus with main renal artery, polar arteries penetrate kidney directly through the capsule from outside of the hilus [27]. During urological procedures and in removal of donor kidneys, awareness regarding these kind of variations will help the surgeons to prevent vascular complications. It is also important for radiologists to interpret angiograms. In selective angiography, the radiologists must be aware of these kind of unusual origins of renal vessels to insert catheter into the correct vessel, which is very important for the accuracy of diagnosis [28] Roopa Kulkarni *et al* reported a rare case of crossed renal ectopia with malrotation in formalin fixed adult cadaver. Kidneys were having arterial feeders from the abdominal aorta and the common iliac arteries and was draining into the inferior vena cava and the right common iliac veins by 5 renal veins[29]. K. Thyagaraju1 and V. Subhadra Devi reported a case of crossed fused left renal ectopia in 24 weeks male fetus with right sided double hila and ureter with accessory renal vessels[30]. Gokhan Gokalp *et al* presented a case with bilateral ectopic kidney and vascular anomaly associated with hypertension and renal dysfunction[31].

## Conclusion

These anomalies of kidney should be in mind during clinical evaluations, imaging and surgical procedures. An accessory artery to inferior pole (polar renal artery) may cross anterior to ureter and obstruct it, causing hydronephrosis. It is important to be aware that the accessory renal arteries are end arteries; consequently, if an accessory artery is damaged or ligated, the part of kidney supplied by it will become ischemic.

## Conflict of Interest

Conflict of interest declared none.

## References

1. Hamilton WJ and Mossman HW, Hamilton, Boyd and Mossman's Human embryology, 4<sup>th</sup> ed. London, The Macmillan Press Ltd.,1976, Urogenital system; 391-2
2. Moore KL and Persaud TVN, The Developing Human, Clinically Oriented Embryology, 8<sup>th</sup> ed. (south asia), Saunders Elsevier Publisher;249-54
3. Sadler TW. Langman's medical embryology. In: Urogenital system. 10th ed; Philadelphia Lippincott Williams & Wilkins 2006; 236.)
4. Benjamin JA, Tobin CE. Abnormalities of kidneys, ureters and perinephric fascia-anatomic and clinical study. J Urol 1951; 65: 715-33.)

5. W.H Hllinshead, C. Rosse, Text book of Anatomy, 4<sup>th</sup> ed. Harper & Row publisher, Philadelphia.;710-11)
6. Bauer SB. Anomalies of the kidney and ureteropelvic junction. In: Walsh PC, Retik AB, Vaughan ED Jr, Wein AJ, editors. Campbell's urology. 7th ed. Philadelphia: WB Saunders; 1998. p. 1708-55.)
7. Claudinei Leôncio Beraldo, Eugênio Fernandes De Magalhães, Demétrius Tierno Martins.,; Thoracic ectopic kidney; J Bras Pneumol 2005; 31(2): 181-3.
8. Kemper MJ, Müller-Wiefel DE. Renal function in congenital anomalies of the kidney and urinary tract. Curr Opin Urol 2001;11:571-5.
9. Cambell MF. Renal ectopy. J Urol 1930; 24:187- 98.
10. Thompson GJ, Pace JM. Ectopic kidney: a review of 97 cases. Surg Gynecol Obstet 1937; 64:935-43.
11. Magak P, King CH, Ileri E et al. High prevalence of ectopic kidney in Cost Province, Kenya. Trop Med Int Health 2004;9(5): 595-600).
12. Muhammad Asghar and Fidaullah Wazir; PREVALENCE OF RENAL ECTOPIA BY DIAGNOSTIC IMAGING; Gomal Journal of Medical Sciences July-December 2008, Vol. 6, No. 2)
13. Campbell MF, Wein AJ, Kavoussi LR. Campbell-Walsh Urology. 9th ed. Philadelphia, PA: Saunders Elsevier, 2007:3279.)
14. Datta AK. Essentials of human embryology. In: Urogenital system. 4th ed; calcutta, India 2000; 219
15. Rascher W, Rosch WH. Congenital abnormalities of the urinary tract. Oxford Textbook of Clinical Nephrology. Oxford: Oxford University Press, Inc, 2005:1402-12.
16. Malek RS, Kelalis PP, Burke EC. Ectopic kidney in children and frequency of association with other malformations. Mayo Clin Proc 1971;46:461-7.)
17. Kang IJ, Lee SH, Lee SM, Lim CH, Yoon JH, Kim TW, Seo SM, Kim BS, Chang YS. A case of congenital single ectopic kidney in pelvis of patients with proteinuria. Korean J Nephrol 2005;24:137-40.)
18. Sashi Kumar, MD; Srinivasa Rao Bolla1, MSc; Venkata Ramana Vollala2, PhD; Unilateral Ectopic Kidney in the Pelvis – A Case Report; Chang Gung Med J 2011;34(6 Suppl):10-2
19. Abbas Fadaii, Somaye Rezaian, Farshad Tojari; Intrathoracic Kidney Presented With Chest Pain; IJKD 2008;2:160-2
20. Belsare SM, Chimmalgi, Vaidy SA. Ectopic Kidney and associated anomalies: A case Report. J Anat Soc India 2002; 51: 236-8.
21. Russell RCG, Williams NS, Bulstrade CJK. Bailey and Love's short practice of surgery. In: The kidneys and ureters. 23<sup>rd</sup> ed; Arnold, London 2000; 1174.
22. Aysel Türkvatan, Tülay Ölçer, Turhan Cumhur; Multidetector CT urography of renal fusion Anomalies;Diagn Interv Radiol 2009; 15:127–134
23. CK Reddy,INA Syed,1 N Satyanarayana,2 MJ Phukon,1 R Dutta,1 P Sunitha3 and PS Devi;Left ectopic kidney with non rotation: a case report; Nepal Med Coll J 2010; 12(2): 123-124
24. Bauer SB. Anomalies of the upper urinary tract. In: Walsh PC, Retik AB, Vaughan ED, Wein AJ, eds. Campbell's urology. 8th ed. Philadelphia: WB Saunders, 2002; 1898– 1906.
25. Bailey SH, Mone MC, Nelson EW. Transplantation of crossed fused ectopic kidneys into a single recipient. J Am Coll Surg 2002; 194:147–50
26. Gray SE, Skandalakis JE. Embryology for surgeons. The embryological basis for the treatment of congenital defects, W.B.Saudners co. Philadelphia, London, Toronto 1972; 472-4.
27. Satyapal KS, Haffejee AA, Singh B, Ramsaroop L, Robbs JV, Kalideen JM: Additional renal arteries: incidence and morphometry. Surg Radiol Anat 2001, 23(1):33-38.
28. Dhar P. An additional renal vein. Clin Anat. 2002; 15: 64–66.
29. Roopa Kulkarni, Ashwini C Appaji, R N Kulkarni; Crossed Renal Ectopia Associated With Malrotation Of Intestine- A Rare Case Report; Int J Anat Res 2013, Vol 1(2):53-56.
30. K. Thyagarajul and V. Subhadra Devi; Crossed Fused Left Renal Ectopia (Cre) In A Fetus With Left Sided Polydactyly - A Case Report International Journal of Basic and Applied Medical Sciences; 2013 Vol. 3 (1) January-March, pp.161-164
31. Gokhan Gokalp, Bahattin Hakyemez and Cuneyt Erdogan; Vascular anomaly in bilateral ectopic kidney: a case report; Cases Journal 2010, 3:5.