

# Kuttner's tumour: a rare case report

Nanda Patil\*, Alok Kumar Yadav#, Shrutika D. Dhawan#

\*Associate Professor, #Tutor, Department of Pathology, Krishna Institute of Medical Sciences, Karad, Maharashtra, INDIA.

Email: [ak.yadav13@gmail.com](mailto:ak.yadav13@gmail.com)

## Abstract

Kuttner's tumour, also known as chronic sclerosing sialadenitis predominantly involves the submandibular gland. Though described more than a century ago, the entity remains under diagnosed and is commonly mistaken for carcinoma. The diagnosis is done by histopathological examination of excised salivary gland which reveals dense lymphoplasmacytic infiltration with acinar atrophy and periductal fibrosis. We present a case of Kuttner's tumour in a 50 year old male patient to highlight its histopathological features and to increase the awareness about this under diagnosed entity.

**Keywords:** Kuttner's tumour, salivary gland.

## #Address for Correspondence

Dr. Alok Kumar Yadav, Associate Professor, Department of Pathology, Krishna Institute of Medical Sciences, Karad, INDIA.

Email: [ak.yadav13@gmail.com](mailto:ak.yadav13@gmail.com)

Received Date: 28/04/2014 Accepted Date: 20/06/2014

### Access this article online

Quick Response Code:



Website:

[www.statperson.com](http://www.statperson.com)

Volume 4  
Issue 3

## INTRODUCTION

Kuttner's tumour, also known as chronic sclerosing sialadenitis is commonly seen in male patients and predominantly affects the submandibular gland.<sup>1,2,3</sup> The entity was first described by Kuttner, a German physician in 1896.<sup>4,5</sup> Its clinical presentation is enlarged firm swelling of submandibular gland which clinically mimics carcinoma, hence remains underdiagnosed.<sup>4,6</sup> The diagnosis is made with the histopathological examination of excised salivary gland which reveals periductal fibrosis, dense lymphoplasmacytic infiltration with lymphoid follicles and loss of acini.<sup>3,7</sup> We present this case to highlight its histopathological features and to increase the awareness about this under diagnosed entity.

## CASE SUMMARY

A 50 year old male patient presented with swelling at right side of neck since 2 years which was gradual in onset. Local examination revealed a 4 x 4 cm, firm

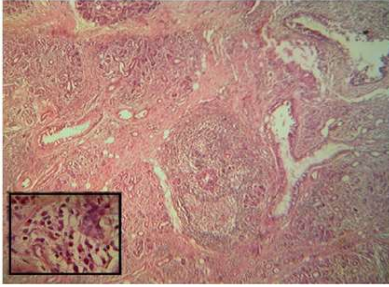
swelling in right submandibular region with mild tenderness. The right cervical lymph nodes were enlarged and non-tender. With the clinical suspicion of carcinoma of submandibular gland, the tumour was excised and sent for histopathological examination.

### Histopathological Features

We received excised specimen of salivary gland (m) 4 x 3.5 x 1.5 cm. Cut section revealed lobulated appearance and firm grey-white areas with a single calculus and attached 2 lymph nodes. Microscopy showed ductal ectasia with extensive periductal fibrosis and surrounding dense inflammatory infiltrate of lymphocytes and plasma cells; in some areas lymphoid formation with reactive germinal centres were noted. The adjacent lymph nodes showed reactive follicular hyperplasia. One year follow up of the patient is uneventful.

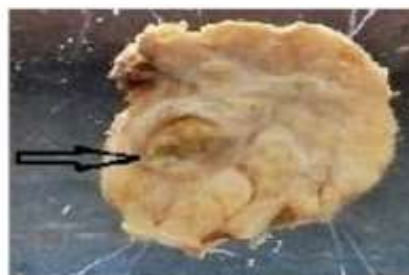

Figure 1: cut section grey-white nodular appearance with an impacted microlith



**Figure 2:** Photomicrograph showing acinar dilatation with periductal lympho-plasmacytic infiltration with a lymphoid follicle. (H and E 100x) Insert- periductal plasma cell infiltration

## DISCUSSION

Kuttner's tumour, also known as chronic sclerosing sialadenitis usually affects the sub mandibular gland and is commonly seen in male patients with mean age of 39 to 45 years. The similar clinical presentation was observed in our case. It often presents as an enlarging firm mass with variable duration for which the clinical diagnosis of a salivary gland carcinoma is usually suggested, as suspected in our case. Cause of inflammation is still unknown, many etiological factors are suggested. Sialoliths are found in 29-83% of cases, which is thought to be important etiological factor. Our case also revealed a sialolith. Other causes include an active local immune reaction, secretary dysfunction with ductal inspissations, abnormality of the duct, infectious agents or autoimmune reaction. Geyer et al and Kitawaga et al have suggested the involvement of IgG4 antibodies with increase number of IgG4 plasma cells as one of the etiological factor.<sup>1,3,9,10</sup> Sonographic appearance and Doppler studies of Kuttner's tumour reveals diffuse involvement with multiple hypoechoic lesions with a heterogenous background and ductal dilatation and calculi.<sup>1</sup> Besides imaging techniques, preoperative FNAC which shows scattered tubular ductal structures on background of lymphoplasmacytic infiltration and fibrous stroma and increased serum IgG4 levels can help to diagnose the disease.<sup>6</sup> The diagnosis is confirmed with histopathological examination of excised tumour which shows dilatation of ducts or marked acinar atrophy, periductal fibrosis and lymphoplasmacytic infiltration.<sup>3</sup> The similar features were noted in our case. Differential diagnosis, besides salivary gland neoplasms, includes tuberculosis, Mikulicz's syndrome, benign lymphoepithelial lesion. Kimuras disease, inflammatory pseudotumour, extranodal marginal zone B-cell lymphoma, sarcoidosis and Castleman's disease.<sup>4,7</sup> Management of Kuttner's tumour can be conservative. Sonographically guided needle biopsy can avoid

operative excision of an otherwise benign condition. Prognosis of Kuttner's tumour is very good which do not tend to recur.<sup>1</sup> Similar good prognosis is observed in our case.

## CONCLUSION

- Kuttner's tumour is thought to be a rare disease as it is usually misdiagnosed for salivary gland neoplasm. Hence, the clinicians should be aware when patient presents with a painless firm enlargement of submandibular gland with or without lymphadenopathy.
- The definitive diagnosis of Kuttner's tumour is done with histopathological examination. USG-guided biopsy should be tried to avoid the unnecessary surgical excision of the entire gland.

## REFERENCES

1. Kiverniti E, Singh A, Clarke P. Kuttner's tumour: an unusual cause of salivary gland enlargement. *Hippokratia* 2008; 12(1):56-58.
2. Agale S.V, Momin Y A, Agale V G. Kuttner Tumor: a report of an under diagnosed entity. *JAPI*, Nov 2010; 58: 694-695.
3. Ellis G, Auclair P. *Tumours of the salivary glands*. Washington DC: Armed Forces Institute of Pathology; 1998:419-49.
4. Sadeghi M, Bakshae M, Emami H et al. Bilateral Kuttner Tumor of submandibular glands: a case report. *Iran J Otorhinolaryngol*; Autumn 2010; 22(61):155-157.
5. Williams HK, Connor R, Edmondson H. Chronic sclerosing sialadenitis of the submandibular and parotid glands: A report of a case and review of literature. *Oral Surg Oral Med Oral Pathol Oral Radiol Endod* 2000; 89:720-3.
6. Chow TL, Tony Chan TF, Choi CY et al. Kuttner's tumour( chronic sclerosing sialadenitis) of the submandibular gland: a clinical perspective. *Hong Kong Med J*; Feb 2008; 14(1):46-49.
7. Mochizuki Y, Omura K, Kayamori K et al. Kuttner's tumor of the submandibular gland associated with fibrosclerosis and follicular hyperplasia of regional lymphnodes: a case report. *J Med Case Reports* 2011; 5:121.
8. Seifert G. Tumor-like lesions of the salivary glands. The new WHO classification. *Pathol Res Pract* 1992; 188:836-46.
9. Harrison JD, Epivatianos A, Bhatia SN. Role of microliths in the aetiology of chronic submandibular sialadenitis: a clinicopathological investigation of 154 cases. *Histopathology* 1997; 31:237-51.
10. Geyer JT, Ferry JA, Harris NL et al. Chronic sclerosing sialadenitis (Kuttner tumor) is an IgG4-associated Disease. *Am J Surg Pathol*; Feb 2010; 34(2):202-210.

Source of Support: None Declared  
Conflict of Interest: None Declared