

Accessory spleen - a case report

Ruta Bapat^{1*}, R A Joshi², V G Sawant³

¹Assistant Professor, ³Head and Professor, Department of Anatomy, Dr DY Patil Medical College, Nerul, Navi Mumbai, Maharashtra, INDIA.

²Head and Professor, Department of Anatomy, RCSM Government Medical College, Kolhapur, Maharashtra, INDIA.

Email: ruta2262@gmail.com

Abstract

During routine dissection, in one of the female cadaver, the accessory spleen was found in the lienorenal ligament. This variation is important for the radiologists and surgeons.

Keywords: Accessary, Lobules, Splenectomy

*Address for Correspondence:

Dr. Ruta Bapat, Assistant Professor, Department of Anatomy, Dr DY Patil Medical College, Nerul, Navi Mumbai, Maharashtra, INDIA.

Email: ruta2262@gmail.com

Received Date: 14/02/2015 Revised Date: 26/03/2015 Accepted Date: 29/04/2015

Access this article online	
Quick Response Code:	Website: www.statperson.com
	Volume 5 Issue 2

develop in one of the peritoneal folds. Thus the accessory spleen is a variant found during development of spleen. It is found commonly near hilum of the spleen and adjacent to the tail of pancreas. The accessory spleen may be embedded partly or wholly in the tail of pancreas or within gastro-splenic ligament.¹ In this case, accessory spleen was found in lienorenal ligament. This ligament connects the anterior surface of left kidney with the hilum of spleen.²

OBSERVATION

In the present study, one accessory spleen was found in the lienorenal ligament. The length of this spleen was 3 cm and breadth was 2 cm. It's structure was confirmed histologically. It was weighing 2.5 gms. The size of the spleen was normal.

INTRODUCTION

The spleen is derived from the mass of mesenchymal cells located between the layers of dorsal mesogastrium. It is lobulated in the fetus but lobules normally disappear after birth. One or more small splenic lobules may

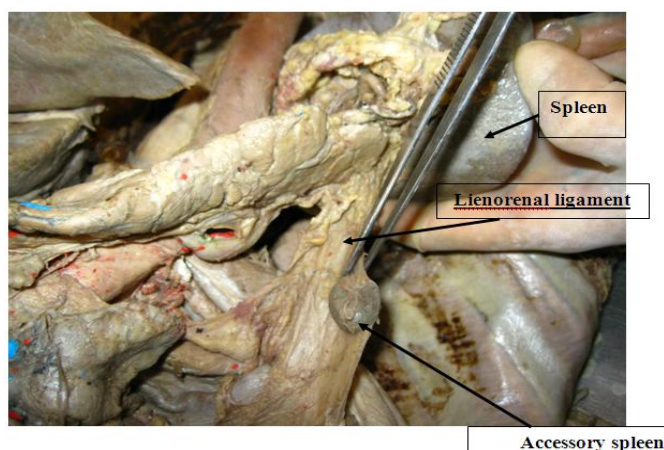


Figure 1: Accessory spleen in lienorenal ligament

DISCUSSION

Splenic clefts, notches, lobulations, an accessory spleen, polysplenia, and wandering spleen are the variants of splenic development.³ The spleen is rarely absent but accessory spleen is fairly common.⁴ Settle EB (1940) found the incidence of accessory spleen in abdominal cavity in between 10% to 35% of individuals and more rarely they were found in scrotum or in liver.⁵ Halpert B and Eaton WL reported that the majority of accessory spleens occur in the neighbourhood of the spleen proper at the hilum, in the gastro-splenic ligament, in the greater omentum, along the splenic vessels and in pancreas. The size of the accessory spleens varied from 0.2 to 3 cm. they reported 10% is the indication of accessory spleen⁶ According to study of Weiland G and Mangold G (2003), accessory spleens may be found in 10% to 15% of the population, in 1% to 2% they were located in the pancreatic tail. Thus, they have to be taken into account in the differential diagnosis of intra- and peripancreatic tumorous lesions.⁷ Mund R. found an accessory spleen on the medial contour of the spleen near the hilum which was a round, iso-echogenic, homogenic and smooth in structure.⁸ The report of Marwan F (1993) concerned with the occurrence of multiple accessory spleens discovered during routine dissection of a male cadaver. Their size ranged from 0.5 to 6 cm in diameter, and they were located in the hilus and ligaments of a spleen with a normal appearance.⁹ Rudowski WJ stated that, in 611 patients who had undergone splenectomy in hematological disorders, accessory spleens were found in 110 patients (18%).¹⁰

APPLIED IMPORTANCE

Accessory spleens may be overlooked during splenectomy. Consequently, a second splenectomy may be necessary. Treatment of an accessory spleen is controversial, as it is usually asymptomatic. When an accessory spleen is located in the abdomen without any symptoms, treatment is not necessary. However, torsion

of the pedicle of the wandering accessory spleen may happen and can result in rupture or infarction.¹¹ Awareness of these variants is important for the radiologist to interpret the findings correctly and avoid mistaking them for a clinically significant abnormality.¹² When an accessory spleen wanders to another place, it may mimic some tumors.³

REFERENCES

1. Moore P. the developing human- clinically oriented embryology, 2003
2. Grays anatomy thirty-eighth ed. Churchill livingstone, 2000
3. Gayer G, Zissin R, Apter S, Atar E, Portnoy O, Itzchak Y. CT findings in congenital anomalies of the spleen. Br J Radiol. 2001; 74:767-772
4. Hollinshead WH. Anatomy for surgeons: The kidneys, ureter and suprarenal glands. 2nd ed Harper and Row publishers, New York, Vol. 2, 1971; 518-573
5. Settle EB. The surgical importance of accessory spleens: with report of two cases. Am J Surg 1940; 50:22
6. Halpert B and Eaton WL. Accessory spleens: A pilot study of 600 necropsies. Anat Rec 1951; 109:371
7. Weiland G and Mangold G. Accessory spleen in the pancreatic tail - a neglected entity? A contribution to embryology, topography and pathology of ectopic splenic tissue. Chirurg. 2003; 74(12):1170-7
8. Mund R. Accessory spleen as a normal variation. PedRad [serial online] vol 2, no. 8.URL: www.PedRad.info/?search=20020827150244
9. Abu-Hijleh MF. Multiple accessory spleens: Case report and literature review. Clinical Anatomy 1993 Volume 6 Issue 4, Pages 232 - 239
10. Rudowski WJ. Accessory spleens: Clinical significance with particular reference to the recurrence of idiopathic thrombocytopenic purpura. World Journal of Surgery 1985; 9(3): 422-430
11. Velanovich V, Shurafa M. Laparoscopic excision of accessory spleen. Am J Surg 2000; 180:62-64
12. Gayer G, Zissin R, Apter S, Atar E, Portnoy O, Itzchak Y. CT findings in congenital anomalies of the spleen. Br J Radiol. 2001; 74:767-772

Source of Support: None Declared
Conflict of Interest: None Declared