

# Role of various parameters of sacrum in determination of sex

Uttama U Joshi<sup>1\*</sup>, Medha Puranik<sup>2</sup>, Manisha R Dhobale<sup>3</sup>, Nitin Mudiraj<sup>4</sup>

<sup>1</sup>Associate Professor, <sup>3</sup>Assistant Professor, <sup>4</sup>Professor and HOD, Department of Anatomy, Bharati Vidyapeeth Deemed University Medical College and Hospital, Sangli-416414, Maharashtra, INDIA.

<sup>2</sup>Professor, Department of Anatomy, Bharati Vidyapeeth Deemed University Medical College and Hospital, Pune, Maharashtra, INDIA.

Email: [uttamajoshi11@gmail.com](mailto:uttamajoshi11@gmail.com)

## Abstract

**Introduction:** The identification of sex in human skeleton is important for many anthropologists, anatomists and forensic experts. Pelvis remains the most reliable region for assessing sex. Sacrum, as a part of pelvis also demonstrates differences. The most useful aspect of such studies is to determine appropriate standards of parameters for sexual dimorphism in different populations. Hence this study was undertaken to evaluate the role of different parameters of sacrum in sex determination. **Materials and Methods:** Study was carried out in Department of Anatomy, BVDU Medical College, Pune. Adult, dry sacra were collected randomly from Anatomy department of different Medical colleges of Maharashtra, with the kind permission of the concerned authorities. 141 sacra were classified in to male and female bones by observing parameters like length of sacrum, width of sacrum, transverse diameter of body of S1, anteroposterior diameter of S1, length of ala of sacrum. **Results:** As a part of univariate analysis, demarcating point (D.P.) was obtained for each of the parameter. The % of bones identified beyond D.P. was found for each of them. The accuracy of this method varied from parameter to parameter. Ventral straight length of sacrum, mid-ventral curved length, anteroposterior and transverse diameter of body of S1 were more in male than female sacra with statistically significant difference in them. Whereas values for the parameters like sacral width (breadth) and length of ala of sacrum were more in female than male sacra with statistically significant difference. **Conclusion:** For different populations based on geographic areas different anthropometric criteria should be applied which could be specific to that particular population. It can be concluded that to identify the sex of sacrum with 100 % accuracy, single parameter was not sufficient instead it requires multiple parameters and indices to reach at the most accurate result.

**Keywords:** sacrum, parameters, ala, length, breadth, sex determination

## \*Address for Correspondence:

Dr. Uttama U. Joshi, Associate Professor, Department of Anatomy, Bharati Vidyapeeth Deemed University Medical College and Hospital, Sangli-416414, Maharashtra, INDIA

Email: [uttamajoshi11@gmail.com](mailto:uttamajoshi11@gmail.com)

Received Date: 13/02/2015 Revised Date: 20/03/2015 Accepted Date: 24/04/2015

Access this article online	
Quick Response Code:	Website: <a href="http://www.statperson.com">www.statperson.com</a>
	Volume 5 Issue 2

## INTRODUCTION

The bones are the last to perish after death, next to the enamel of teeth. The examination of bones play important role in determination of sex, age, race and region. Thus, many times forensic experts, anatomists,

paleoanthropologists are called upon to determine the sex of skeletal remains to establish the identity of the individual. Every region and element of the skeleton has been used to develop methods for sex determination with varying degrees of success. The bones that are related with weight bearing and those concerned with specific function related to either of the sex show certain peculiar features in size, shape, muscular markings etc. Stewart<sup>1</sup> in 1954 has quoted that sex identification in human skeleton remains is an important component of many anthropological investigations and such investigation should be based on observations and measurements of the entire skeleton to be meaningful. The determination of sex from bones can be done by- visual morphological assessment and by using various metrical methods of analysis. Statistical methods are more reliable and accurate than visual morphological methods. The sacrum

has always attracted the attention of medicolegal experts for establishing sex. Sacrum is an important part of axial skeleton. It supports the erect spine and contributes to the strength and stability of the bony pelvis to transmit the body weight and allows considerable mobility in childbearing. Pearson's K.<sup>2</sup> used univariate analysis method while Flander<sup>3</sup> and Fisher<sup>4</sup> adopted the use of univariate as well as multivariate methods of sexing sacrum. Krogman<sup>5</sup> rated accuracy of sex determination using- Pelvis (95%), Skull (90%), Pelvis + skull (98%), Long bones (80%). Metrical study of sacrum in early days has been done by various authors like Fawcett E<sup>6</sup>, Davingvon V<sup>7</sup>. Calculation of demarcating point for various parameters can identify the sex with 100% accuracy. Singh *et al* have reported that even within the same general population, mean value may be significantly different in bones from different zones. So the demarcating point should be calculated separately for different regions of population. As India is a vast country with intermixing of races, the comparison and verification of findings from different parts and regions of country are essential. Though the literature on the sacral morphometry is available from other regions of country there is paucity of the population specific data from the Maharashtra region. Thus the present study was planned to study the sex differences of different parameters of sacrum and compare the findings with the other studies of different regions.

### MATERIALS AND METHODS

This was a cross sectional study, approved by IEC. 141 dry and fully ossified adult human sacra were collected randomly from Anatomy department of different Medical colleges of Maharashtra, with the kind permission of the concerned authorities. The measurements were taken with Digital Vernier caliper, Standardized flexible steel tape and Marker pen. In order to avoid observer's error, all the parameters were measured and recorded single handedly. For each of the parameters, three readings were taken and then their mean was taken as final reading. The 141 normal sacra were studied. In these 141 sacra sex was morphometrically determined. The bones were classified in to male and female bones by observing and measuring

### RESULTS

Each parameter was statistically studied by calculating mean, standard deviation (S.D.), 'Z' value, 'p' value and

parameters like length of sacrum, width of sacrum, transverse diameter of body of S1, anteroposterior diameter of S1, length of ala of sacrum. The measurements were recorded in mm by Vernier caliper accurate to 0.1 mm as follows.

- 1. Maximum Length. (Ventral straight length):** Straight length was measured in mm from the midpoint of upper border of body of S1 (anterosuperior margin of promontory) to midpoint of anteroinferior margin (Apex) of S5 vertebra. (Photograph No 1)
- 2. Maximum Width (Breadth) of sacrum:** This was maximum distance measured in mm between two points at the lateral most anterior part of alae of sacrum, at the level of S1 vertebra. (Photograph No 2)
- 3. Midventral Curved length of sacrum:** It was measured in centimeters by using flexible steel tape between a midpoint of the anterosuperior border of sacral promontory to a midpoint of anteroinferior margin (apex) of S5 vertebra. It was converted into millimeters.
- 4. Anteroposterior Diameter of body of S1 vertebra:** It was measured between a midpoint on the promontory and mid point on posterior-superior border of S1 body. (Photograph No 3)
- 5. Transverse diameter of Body of S1 vertebra:** It was recorded by taking midpoints of lateral margins of superior surface of body of S1 vertebra. (Photograph No 4)
- 6. Length of Ala:** It was recorded as follows. - Distance between a point taken as lateral most point on superior surface of body of S1 vertebra and another point on lateral most part of ala. It was recorded on right as well as on left side and their mean was taken as the final length of alae. (Photograph No 5)

### Statistical Methods

The data was analyzed into range, mean, standard deviation etc by a standard computerized program. Comparison of each study factor was done by applying

1. 'Z' Test and obtaining 'p' value.
2. Calculation of demarcating point (D.P.)

demarcating point (D.P.). Percentage of bones identified beyond D.P. i.e. without overlapping was calculated for each parameter.

**Table 1:** Comparison of ventral straight length of sacrum

No	Title	Males	Females
1	No. of bones	72	69
2	Range (mm)	80.15-120.46	70.01-108.38
3	Mean(mm)	100.61	89.91
4	Standard Deviation	7.58	7.95

5	Z Value	8.17	
6	P Value	<0.0001	
7	Statistically Significant or not	significant	
8	Mean + / - 3 SD(mm)	77.87-123.34	66.07-113.74
9	Demarcating Point(D.P.)	>113.74	<77.87
10	% of Bones identified	2.78	7.25

The mean value for male sacra was 100.61 mm and for female was 89.91 mm. The findings showed that ventral straight length of male sacra was significantly higher than that of female sacra. The demarcating point for male was

>113.74 mm and for female was <77.87mm. 2.78% of male and 7.25% of female sacra could be identified beyond DP.

**Table 2: Comparison of sacral width (breadth)**

No	Title	Males	Females
1	No. of bones	72	69
2	Range (mm)	91.83-117.19	91.83-117.19
3	Mean(mm)	102.53	105.07
4	Standard Deviation	6.23	5.57
5	Z Value		2.55
6	P Value		<0.05
7	Statistically Significant or not		<b>Significant</b>
8	Mean + / - 3 SD(mm)	83.84-121.23	88.36-121.78
9	Demarcating Point	<88.36	>121.2
10	% of Bones identified	1.39	0

The mean value for male sacra was 102.53 mm and for female was 105.07 mm. The findings showed that sacral width (breadth) of female sacra was significantly higher

than that of male sacra. The demarcating point for male was <88.36 mm and for female was >121.2 mm. 1.39% of male sacra could be identified beyond DP.

**Table 3: Comparison of mid -ventral curved length**

No	Title	Males	Females
1	No. of bones	72	69
2	Range (mm)	95-140	88-116
3	Mean(mm)	110.83	100.92
4	Standard Deviation	8.78	6.92
5	Z Value		7.46
6	P Value		<0.0001
7	Statistically Significant or not		<b>significant</b>
8	Mean + / - 3 SD(mm)	84.48-137.18	80.14-121.69
9	Demarcating Point	>121.78	<84.84
10	% of Bones identified	9.72	0

The mean value for male sacra was 110.83 mm and for female was 100.92 mm. The above findings showed that mid ventral curved length of male sacra was significantly higher than that of female sacra. Demarcating point

suggested that any sacrum measuring >121.78 mm was male and < 83.84 mm was female. 9.72% of male sacra could be identified beyond DP.

**Table 4: Comparison of antero-posterior diameter of body of S1**

No	Title	Males	Females
1	No. of bones	72	69
2	Range (mm)	19.3-33.14	13.43-33.99
3	Mean(mm)	28.02	26.74
4	Standard Deviation	2.49	3.22
5	Z Value		2.63
6	P Value		<0.01
7	Statistically Significant or not		Significant
8	Mean + / - 3 SD(mm)	20.56-35.49	17.09-36.39
9	Demarcating Point	>36.39	<20.56
10	% of Bones identified	0	1.45

The mean value for male sacra was 28.02 mm and for female was 26.74 mm. The finding showed that antero-posterior diameter of body of S1 vertebra of male sacra was significantly higher than that of female. Demarcating

point suggested that any sacrum measuring > 36.39 mm was male and < 20.56 mm was female. 1.45% female sacra could be identified beyond DP.

**Table 5:** Comparison of transverse diameter of body of S1

No	Title	Males	Females
1	No. of bones	72	69
2	Range (mm)	35-56.46	31.22-51.41
3	Mean(mm)	44.18	41.17
4	Standard Deviation	3.66	4.30
5	Z Value		4.47
6	P Value		<0.0001
7	Statistically Significant or not		Significant
8	Mean + / - 3 SD(mm)	33.20-51.15	28.26-54.07
9	Demarcating Point	>54.07	<33.20
10	% of Bones identified	1.39	2.9

The mean value for male sacra was 44.18 mm and for female was 41.17 mm. The above finding showed that transverse diameter of body of S1 in male sacra was significantly higher than that of female sacra. The

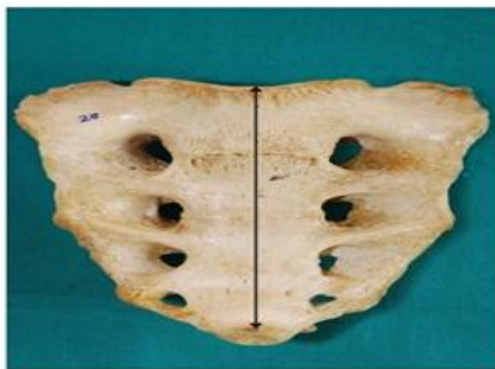demarcating point suggested that any sacrum measuring > 54.07 mm was male and < 33.20 mm was female. 1.39% of male and 2.9% of female sacra could be identified beyond DP.

**Table 6:** Comparison of mean length of ala of sacrum

No	Title	Males	Females
1	No. of bones	72	69
2	Range (mm)	24.33-38.26	25.20-37.01
3	Mean(mm)	30.35	32.33
4	Standard Deviation	3.39	2.92
5	Z Value		3.72
6	P Value		<0.001
7	Statistically Significant or not		significant
8	Mean + / - 3 SD(mm)	20.17-40.53	23.58-44.08
9	Demarcating Point	<23.58	>40.53
10	% of Bones identified	0	0

The mean value for male sacra was 30.35 mm and for female was 32.33 mm. The above findings showed that mean length of ala was more in female than male sacra. Demarcating point suggested that any sacrum measuring

< 23.58 mm was male and > 40.53 mm was female. There was complete overlapping of values for male and female sacra so could not be identified beyond DP.



**Figure 1:** Ventral Straight length



**Figure 2:** Maximum width of sacrum

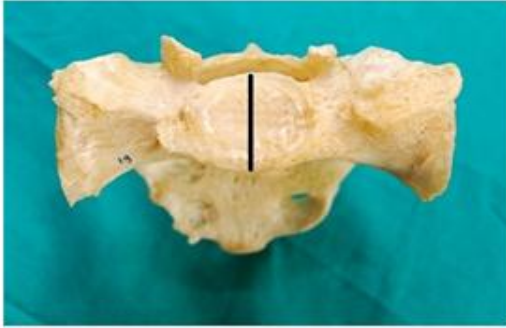


Figure 3: Anteroposterior Diameter of body of S1 vertebra



Figure 4: Transverse Diameter of body S1 vertebra

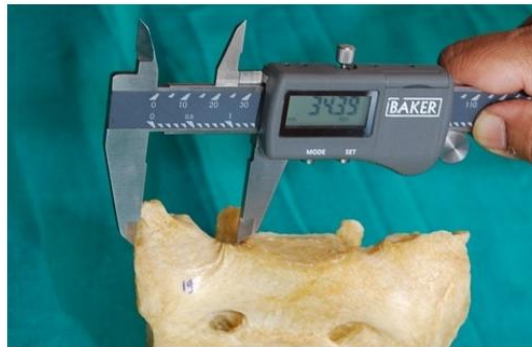

Figure 5: Length of Ala of sacrum

## DISCUSSION

Williams and Warwick<sup>8</sup>, while commenting upon sexual dimorphism stated that in general the female bones are usually smaller and of less diameter than the male bones. They stated that pelvis remains the most reliable region for assessing sex. Sacrum, as a part of pelvis also demonstrates differences which should be standardized for the purpose of identification. In univariate method of analysis, if the sexing is done on the basis of demarcating point (D.P.), calculated for each parameter the chances of wrong diagnosis of sex are negligible. It is calculated by adding and subtracting 3 X standard deviation (S. D.) to and from the mean of any parameter. Raju and Singh<sup>9</sup> have called such calculated range as demarcating point which identifies sex with 100 % accuracy from any given

bone. The demarcating points of various parameters if crossed by any sacrum will identify the sex with certainty which is important in medico legal cases. However it is not necessary for any bone to cross the D.P. of all the parameters. Any single D.P. for any of the parameters, if crossed would detect the sex with 100 % accuracy<sup>9</sup>. In the present study, the parameters like – ventral straight length of sacrum, mid-ventral curved length, anteroposterior diameter of body of S1, transverse diameter of body of S1 were more in male sacra than female sacra with statistically significant difference in them. Whereas values for the parameters like sacral width (breadth) and length of ala of sacrum were more in female sacra than male sacra with statistically significant difference in them.

Table 1: Ventral Straight Length

Investigators	Male				Female				(S.S.D.)
	N	X	Range	S.D.	N	X	Range	S.D.	'P' Value
Davinvong	50	96.5	77-110	8.8	50	88.1	71 - 105	6.87	< 0.001
Flander(white)	50	110.2	---	11.4	50	109.6	---	12.56	NS
Black	50	105.5	---	11.4	50	99.8	-- ---	11.24	NS
Raju <i>et al</i>	33	104.9	79-130.8	8.64	11	92.7	75.9 -109.6	5.61	< 0.001
Siddiqui	105	104.9	89 - 125	6.3	76	91.1	78 - 107	0.62	< 0.001
Mishra S.R.	74	107.53	92 - 122	7.03	42	90.58	84 - 100	4.42	< 0.001
Renuka	150	107.41	89 - 123	5.62	150	92.57	68 - 119	8.51	< 0.01
Present study	72	100.61	80.1-120.4	7.58	69	89.91	70.01-108.38	7.95	< 0.001

**Ventral Straight Length:** The values were higher in male sacra than the female sacra. The findings of present study (mean, S.D, ‘p’ value) coincided with most of the workers like Davinvongs<sup>7</sup>, Raju *et al*<sup>9</sup>, but do not with Flander<sup>3</sup>. According to him this parameter was statistically not significant.

**Table 2: Maximum Width of Sacrum**

Investigators	Male				Female				(S.S.D.)
	N	X	Range	S.D.	N	X	Range	S.D.	'P' Value
Davinvong	50	99.9	85 - 109	5.02	50	101.1	92 - 113	5.12	NS
Flander(white)	50	116.4	---	7.11	50	117.4	---	7.08	NS
Black	50	118.8	---	7.81	50	111.8	---	7.23	NS
Raju <i>et al</i>	33	105.3	89 -121.3	5.31	11	103	92.3 -113.2	3.6	NS
Siddiqui	105	102.9	90 - 116	4.9	76	103.9	88 - 118	5	NS
Mishra S.R.	74	105.35	95 - 120	6.22	42	105.7	92 - 118	6.32	NS
Renuka	150	101.15	90 - 118	5.4	150	104.1	87.5 -116.6	5.93	NS
Present study	72	102.53	84.03-121.23	6.23	69	105.07	91.83-117.19	5.57	<0.05

**Maximum Width of Sacrum:** The findings for this parameter didn't match with the other workers because statistically significant difference was not found in other workers.

**Table 3: Midventral Curved Length**

Investigators	Male				Female				(S.S.D.)
	N	X	Range	S.D.	N	X	Range	S.D.	'P' Value
Davinvong	50	104.3	82 - 115	0.71	50	97.1	81 - 110	6.67	< 0.001
Flander(white)	50	128.3	---	1.41	50	124.7	---	12.9	NS
Black	50	120.9	---	1.17	50	111.7	---	10.9	<0.01
Raju <i>et al</i>	33	112.7	92.5 -133	0.675	11	104.8	84.5 - 125	6.74	< 0.01
Siddiqui	105	104.9	89 - 125	6.3	76	103.9	93 - 127	5.5	< 0.001
Mishra S.R.	74	119.56	96 - 136	8.61	42	100.95	90 - 115	6.2	< 0.001
Renuka	150	116.48	96 - 134	5.93	150	110.89	91 - 130	7.8	< 0.001
Present study	72	110.83	95- 140	8.78	69	100.92	88- 116	7.46	< 0.001

**Midventral Curved Length:** Thus the findings of present study (mean, S.D, ‘p’ value) coincided with most of the workers, and more with Raju *et al*<sup>9</sup> but according to Flander<sup>3</sup> this parameter was statistically significant in black races but not in white races.

**Table 4: Antero-Posterior Diameter of Body of S-1 Vertebra**

Investigators	Male				Female				(S.S.D.)
	N	X	Range	S.D.	N	X	Range	S.D.	'P' Value
Davinvong	50	29.7	25 - 37	2.29	50	27.5	25 - 31	1.48	< 0.001
Flander(white)	50	33.5	---	3.21	50	29.6	---	1.82	< 0.01
Black	50	33.5	---	2.1	50	28.8	---	2.83	< 0.01
Raju <i>et al</i>	33	30.3	21.6- 38.9	2.88	11	27.6	20 - 36	2.8	< 0.001
Siddiqui	105	29.5	23 - 37	2.4	76	27.7	22 - 34	2.1	< 0.001
Mishra S.R.	74	30.4	26 - 37	2.58	42	29.29	24 - 32	2.15	< 0.001
Renuka	150	29.7	20.4 -53.5	3.21	150	28.4	22-38	2.57	< 0.01
Present study	72	28.02	19.3- 33.1	2.49	69	26.74	13.4-33.99	2.63	< 0.01

**Table 5: Transverse Diameter of Body of S-1 Vertebra**

Investigators	Male				Female				(S.S.D.)
	N	X	Range	S.D.	N	X	Range	S.D.	'P' Value
Davinvong	50	47.4	36 - 53	3.99	50	44.1	36 - 50	3.68	< 0.001
Flander(white)	50	52.7	---	5.21	50	46.5	---	3.94	< 0.01
Black	50	54.5	---	4.25	50	47.4	---	4.15	< 0.01
Raju <i>et al</i>	33	47.3	32.1 -62.6	5.09	11	42.1	35.6 - 48.6	5.09	< 0.01
Siddiqui	105	49.2	36.62	4	76	42.4	34 - 49	3.5	< 0.001
Mishra S.R.	74	49.12	42 - 55	3.27	42	42.81	40 - 50	3.04	< 0.001
Renuka	150	46.78	36.1 - 57	3.96	150	43.11	31.6 - 54	4.59	< 0.01
Present study	72	44.18	35 - 56.46	3.66	69	41.17	31.2 - 51.4	4.30	< 0.001

**Table 6:** Length of Ala of Sacrum

Investigators	Male				Female				(S.S.D.)
	N	X	Range	S.D.	N	X	Range	S.D.	'P' Value
Siddiqui	105	28.9	21.5-35.5	2.7	76	31.9	24 - 38.5	3.1	< 0.001
Mishra S.R.	74	28.38	23-33	2.67	42	31.67	26-39	3.08	< 0.01
Renuka	150	29.74	22.5-38.3	2.99	150	30.77	22.7- 38.5	2.87	< 0.01
Present study	72	30.35	24.3-38.2	3.39	69	32.33	25.2-37.01	2.92	< 0.001

The findings of present study (mean, S.D, 'p' value) for parameters like anteroposterior diameter of body of S-1, transverse diameter of body of S-1 vertebra, length of ala of sacrum coincided with most of the workers.

## CONCLUSION

As a part of univariate analysis, demarcating point (D.P.) was obtained for each of the parameter. The % of bones identified beyond D.P. was found for each of them. The accuracy of this method varied from parameter to parameter. The present study showed that certain parameters like - ventral straight length of sacrum, mid-ventral curved length, anteroposterior diameter of body of S1, transverse diameter of body of S1 measured more in male sacra than female sacra with statistically significant difference in them. Whereas values for the parameters like sacral width (breadth) and length of ala of sacrum were more in female sacra. It can be concluded that to identify the sex of sacrum with 100 % accuracy single parameter is not sufficient instead it requires multiple parameters and indices to reach at the most accurate result. Thus for different populations based on geographic areas different anthropometric criteria should be applied which could be specific to that particular population. The knowledge of the anatomy and sexual dimorphic features of sacrum will definitely help in medico legal practice.

## REFERENCES

1. Stewart T.D.: Evaluation of the evidence from the skeleton. In the Legal Medicine era, 1954;407-450
2. Pearsons K.: On problem of sexing osteometric material. *Biometrika* 10, 479- 81
3. Flander L.: Univariate and Multivariate methods of sexing the sacrum. *Am. J Phys. Anthropology*, 1978; 49: 103-110.
4. Fisher R. A.: The use of multiple measurements in taxonomic problems.1936 *Ann ---Egenetics*, 179-88, cited by Giles. (1970)
5. Krogman W. M.: The human skeleton in legal medicine. Medical aspects. In *Symposium of Medical problems Series II* Levingson S. A. Editor Lippincott Philadelphia.1949
6. Fawcett F.: The sexing of the human sacrum. *Journal of anatomy*. 1938; 72:633
7. Davinvongs V.: The pelvic girdle of the Australian Aborigine, sex differences and sex determination. *Am. Phys. Anthropology*, 1963; 21(4): 443-455
8. Williams and Warwick.: *Gray' s Anatomy* (1995); 38<sup>th</sup> Edn : 528- 531
9. Raju P. B, Singh S. P.: Identification of sex from hip bone Demarcating Points. *Journal of Anatomical society of India*, 1977; 26: 111-117.
10. Siddiqui.: Dissertation for M.S. Anatomy, 2000.
11. Mishra S. R, Singh J. et al.: Identification of sex of sacrum of Agra region. *Journal of Anatomical society of India*, 2003; 52 (2): 132-136
12. Renuka: Sacrum: A Tool for Sex Identification M.S. (Anatomy) Dissertation, 2007.

Source of Support: None Declared  
Conflict of Interest: None Declared