

# Single incision two ports and two slings technique of laparoscopic cholecystectomy – A retrospective analysis of our practise

Loganathan Mannu<sup>1</sup>, Habeeb Mohammed Shajahan<sup>1</sup>, Balakrishnan V<sup>2</sup>, Karunanithi Ramaiah<sup>2</sup>, Natarajan Ramalingam<sup>3\*</sup>

<sup>1</sup>Associate Professor, <sup>2</sup>Professor, <sup>3</sup>Assistant Professor, Department of Surgery, Chettinad Hospital and Research Institute, IT Highway, Kelambakkam- 603 103, Kancheepuram District, Tamilnadu, INDIA.

Email: [drlogu.mannu@gmail.com](mailto:drlogu.mannu@gmail.com), [dr\\_abee@yahoo.com](mailto:dr_abee@yahoo.com), [sathyanataraj78@gmail.com](mailto:sathyanataraj78@gmail.com), [rknithi2000@yahoo.co.in](mailto:rknithi2000@yahoo.co.in), [surgnutty@gmail.com](mailto:surgnutty@gmail.com)

## Abstract

**Background:** Since the advent of Single incision laparoscopic surgery, there has been genuine effort from the Laparoscopic fraternity to improvise the technique and make it safe, lesser discomfort and cost effective for the patients. One such effort is the use of standard laparoscopic trocars and instruments in accomplishing Single incision laparoscopic surgery. Various modifications have been introduced by various surgeons all over the world. Our modification is the first instance in literature, where cholecystectomy using standard laparoscopic instruments in single incision, has been done with only two ports. Here we analyse the expediency, safety, benefits, and drawbacks of our practice. **Methods:** For a duration of 2 years, 65 patients with cholelithiasis without any complications were operated upon by our modified single incision laparoscopic technique. Results were analysed. **Results:** All 65 patients were successfully operated upon by SITPS (Single incision two ports and two slings) technique. VAS score <4 in 64 patients and >5 in one patient. There was no significant postoperative complications. Seven patient had port site edema. No patient had port site infection. There was no incidence of port site hernia after one year follow up. **Conclusion:** SITPS technique of laparoscopic cholecystectomy is a technically feasible and safe alternative to standard laparoscopic approach, with reduced postoperative pain, with no visible scar and hence cosmetically superior.

**Keywords:** Cholecystectomy, Port-site hernia, SITPS - Single incision two ports and two slings.

## \*Address for Correspondence:

Dr. Natarajan Ramalingam, B8, Plaza Court, No.28, Church Road, Perungudi, Chennai – 600 096, Tamilnadu, INDIA.

Email: [surgnutty@gmail.com](mailto:surgnutty@gmail.com)

Received Date: 17/05/2015 Revised Date: 26/06/2015 Accepted Date: 29/07/2015

Access this article online	
Quick Response Code:	Website: <a href="http://www.statperson.com">www.statperson.com</a>
	Volume 5 Issue 3

## INTRODUCTION

The concept of a procedure being stated as ‘minimally invasive’ is not constant. Surgical techniques are constantly developing in such a way that, sooner or later the procedures which we consider minimally invasive in the present era may no longer be so, as lesser invasive techniques keeps evolving. Single incision laparoscopic

surgery is considered one such station in this path of development of minimally invasive surgery. Laparoscopic cholecystectomy was performed with four ports using one instrument for each port traditionally. With developments in instrumentation, the concept of using multiple instruments via a single port was developed. The first citation of the single incision Laparoscopic technique of cholecystectomy was in 1997 by Navarra *et al*<sup>1</sup>. Since then many authors have developed this technique and modified it in various ways. Worldwide, at least 12 different variations of Single incision laparoscopic techniques have been described. Laparoscopic Cholecystectomy through four port technique has been considered as the gold standard in the treatment of gall stones. Though laparoscopic cholecystectomy still hold the same place, surgeons are constantly trying to improvise the approach of laparoscopy in an attempt to make it better for the patient in every possible way it can be. One such improvised

approach is the Single incision laparoscopic surgery. It doesn't stop there. The approach of SILS itself is continuously changing in various ways. A novel technique, modified, refined and practiced by us is the Single incision, two ports, and two slings approach in performing Laparoscopic cholecystectomy without the need for specialized single port device or any expensive articulating laparoscopic instruments.

## MATERIALS AND METHODS

### Patient selection

Between July 2012 and June 2014, 65 patients underwent Single incision laparoscopic cholecystectomy. All patients were successfully operated by this technique and no patients were converted to standard laparoscopic procedure or open procedure. After preoperative assessment and obtaining an informed consent, including the necessity of conversion to open procedure if need arises, all patient were subject to our modified technique.

### Surgical Technique of Single Incision Two port Cholecystectomy

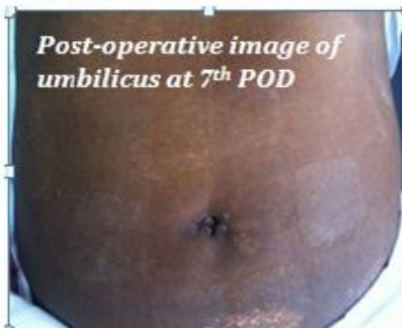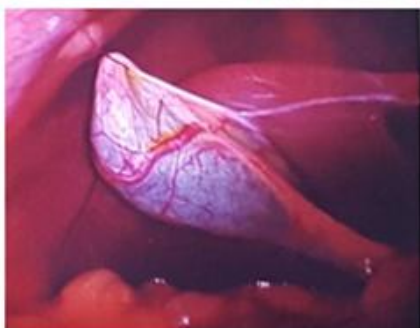
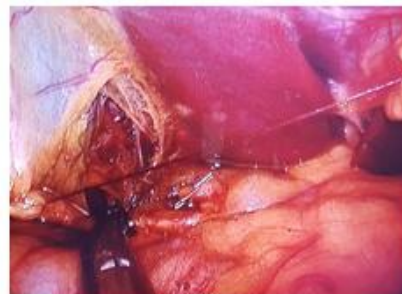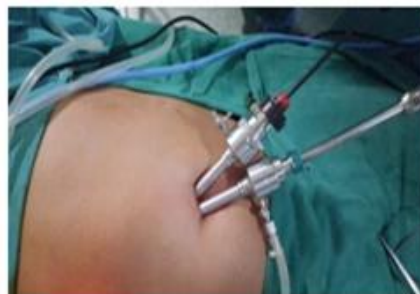Patient is placed supine and strapped to the operating table. Head end of the table raised to about 15-30°, and right side at a higher level than left to make the bowel and omentum fall away from the operating site. Umbilicus is lifted and a curvilinear 1.5 – 2cm incision is placed in the inferior circumference of the umbilicus. Supra facial

dissection in the subcutaneous plane is done, and anterior rectus sheath is cleared of fat. CO<sub>2</sub>pneumoperitoneum is created with veress needle. A 10mm port is placed at 8'o clock position and 5mm or 10 mm port is placed at 4'o clock position (depending on the availability of 5mm or 10mm scope). Initial visualisation of the entire peritoneal cavity is done. Sling 1 is introduced from right hypochondrium for fundal retraction. Sling 2 applied from anterior axillary line to infundibulum of gall bladder and brought out through the epigastrium at the midline, used for retraction, visualisation and dissection of the Calot's triangle. 2.0 Vicryl is used for to make the slings. Calot's triangle is carefully dissected with monopolar and bipolar diathermy as required. Cystic artery and Cystic duct is skeletonised. Both structures are doubly clipped and divided. Gall bladder is dissected free from liver in toto and delivered through the 10mm port using endobag technique.

Both ports are clearly visualised and closed individually with 2PDS. Skin is closed 4.0 monocryl sub-cuticular suture

### Postoperative period

All patients were given three doses of prophylactic antibiotic (induction, 8hrs postop and 16hrs postop). All patients received 2 doses of paracetamol 1gram, and diclofenac 75mg. Supplementary dose of Tramadol 50mg was given as and when required.



## RESULTS

Over a period of 2 years, 65 patients (41 women and 24 men) of age ranging from 23 to 72 years (mean age 42.1 years) with uncomplicated cholelithiasis were operated

upon by SITPS (Single incision, two ports, and two slings) technique of cholecystectomy. Of these 47 patients had fairly controlled Diabetes mellitus type II and 23 had well controlled hypertension. The BMI of 56

patients were <30 and the remaining 9 patients had BMI 30-35. The mean operating time was 63 minutes. Visual analogue scale (VAS) was less than 4 in 64 patients at 8 hours postop, and less than 3 at 16 hours post op. One patient had VAS score more than 5, for which he was given 2 doses of supplemental Tramadol. 62 patients were discharged on the 2<sup>nd</sup> post-operative day. 2 patients were discharged on 3<sup>rd</sup> postoperative day for social reasons. One patient's stay was prolonged to 4 days, due to persistent pyrexia, eventually turned out to be a Urinary tract infection, for which he was given extended dose of antibiotic. Notably seven patients developed edema and in duration of the umbilical region, which resolved spontaneously by one week in all patients. The incidence of such edema correlated with obesity (all patients with BMI 30-35), as extensive umbilical dissection was required to access the rectus sheath. There was no incidence of wound infection in the immediate follow up. There was no incidence of port site hernias over a period of one year follow up. Most of the patients returned to their routine activities within a week after discharge.

## DISCUSSION

Single Incision Laparoscopic approach has been accepted as a viable and better alternate to the standard laparoscopic approach for various procedures worldwide, including bariatric surgeries. Is there any real benefit with SILS approach over standard approach, is what remains unanswered. But results from various studies, have proven it to be at least equivalent to the standard approach. The procedure does not require any sophisticated expensive ports or articulating instruments to fulfil the principles of ergonomics. The single incision technique with conventional instruments has redefined the operating principles of laparoscopic surgery. Various studies has proved that the SILS approach can be performed with standard laparoscopic instruments<sup>2-5</sup> In our series of 65 patients we have routinely used two ports (one 10mm and one 5mm or two 10mm ports), through two separate fascial incisions. In one study, by Sinha *et al*<sup>6</sup>, has used three ports (One 10mm and two 5mm ports) without the need for sling. The use of two slings in our technique has reduced the number of ports to two. This has not only reduced the size of the skin incision necessary, but also decreased the cumulative size of defect in fascia. One of the advantages we felt in this approach over the standard approach is the exact visualisation of the fascial defect and perfect closure of the ports individually, hence decreasing the chance of port site hernia. Also when compared to the three port single incision technique, as the size of the defect is reduced the chances of port site hernia is much less, as clearly evident from our small series, where no such cases

of port site hernia were reported. Another particular advantage is the ease of delivery of the Gall bladder. The largest stone in the gall bladder we have removed is 1.3cm, without any difficulty, and without the need for widening the size of the port. In a randomised, prospective study involving single-blind comparison of laparoscopic and small-incision cholecystectomy in 1996, Majeed, *et al*<sup>7</sup>, has quoted small-incision cholecystectomy to take much lesser time than a standard Laparoscopic Cholecystectomy. He has also mentioned that laparoscopic approach has no significant advantage over small incision approach, considering hospital stay and postoperative recovery. While in a comparative continuing study the author has quoted the mean operating time of standard multiport laparoscopic cholecystectomy in uncomplicated cases as 18.4 minutes and 24.7 minutes using single incision technique<sup>6</sup>. Though in our series, the mean operating time was 63 minutes, on climbing up the learning curve, the operating time will be much shorter especially with better understanding of the compromise in ergonomics and regular practice of the technique. Various advantages with this single incision technique which we felt over the standard laparoscopic approach are better cosmesis, ease of tissue removal, decreased postoperative pain and analgesic requirement.

## CONCLUSION

The retrospective analysis of our practice of accomplishing cholecystectomy with single incision and two ports, has proven that this approach is equivalent to results from standard approach with reduced postoperative pain, and excellent cosmetic results.

## FUTURE

The series requires large volume of patients and comparative analysis of standard and the modified single incision approach, to evaluate the incidence of post-operative infection and port site hernias and to evaluate the statistical difference between the two approaches.

## REFERENCE

1. Navarra, G., et al., One-wound laparoscopic cholecystectomy. *Br J Surg*, 1997. 84(5): p. 695.
2. Chow, A., et al., Single-incision laparoscopic surgery for cholecystectomy: an evolving technique. *Surg Endosc*, 2010. 24(3): p. 709-14.
3. Hodgett, S.E., et al., Laparoendoscopic single site (LESS) cholecystectomy. *J Gastrointest Surg*, 2009. 13(2): p. 188-92.
4. Piskun, G. and S. Rajpal, Transumbilical laparoscopic cholecystectomy utilizes no incisions outside the umbilicus. *J Laparoendosc Adv Surg Tech A*, 1999. 9(4): p. 361-4.

5. Romanelli, J.R., et al., Single-port laparoscopic cholecystectomy: initial experience. *Surg Endosc*, 2010. 24(6): p. 1374-9.
6. Sinha, R. and A.S. Yadav, Transumbilical single incision laparoscopic cholecystectomy with conventional instruments: A continuing study. *J Minim Access Surg*, 2014. 10(4): p. 175-9.
7. Majeed, A.W., et al., Randomised, prospective, single-blind comparison of laparoscopic versus small-incision cholecystectomy. *Lancet*, 1996. 347(9007): p. 989-94.

Source of Support: None Declared  
Conflict of Interest: None Declared