

Clinico radiological correlation of psoriatic arthropathy- A prospective study

K Parimalam^{1*}, R Subha², M Ananthi², V Suganthi², B Karpagam²

¹Professor and HOD, ²Assistant Professor, Department of Dermatology, Government Villupuram Medical College, Tamil Nadu, INDIA.

Email: subhasound@gmail.com, drananthi@yahoo.com, suganthivalavan@gmail.com, drbkarpagam@gmail.com

Abstract

Psoriatic arthropathy [PsA] is one of the common seronegative spondyloarthropathies. It was in the mid-19th century that an association between psoriasis and joint involvement first made when, apart from the clinical findings, diagnosis of PsA was based mainly on conventional radiography. In the recent times, imaging techniques like magnetic resonance imaging [MRI] and ultrasonography [USG] have been increasingly used in the diagnosis and management of PsA. The interpretations provide additional clues to the pathogenesis of this progressive and sometimes mutilating disease. A positive radiological finding using X ray means an advanced disease, and hence the need for better imaging studies which can detect the pathology much earlier. As is well agreed upon, early detection of articular and peri-articular inflammation will help timely initiation of appropriate therapy to prevent further progression of the inflammation and thereby prevent joint destruction. USG is more effective than X ray and less expensive than and having more or less equal diagnostic potential as MRI. USG is a reliable investigatory tool freely available in many centers and should be made use of in the diagnosis and follow up of patients with PsA

Keywords: Psoriatic arthritis; Ultrasound

*Address for Correspondence:

Dr. Parimalam Kumar, New No 4/1, East Ellaiamman Koil Street, Thiruvottiyur, Chennai -600019, Tamil Nadu, INDIA.

Email: drparimalam@gmail.com

Received Date: 14/11/2015 Revised Date: 22/12/2015 Accepted Date: 20/01/2016

Access this article online	
Quick Response Code:	Website: www.statperson.com
	Volume 6 Issue 1

INTRODUCTION

With the advancement in the clinical classification and diagnostic procedures, currently the prevalence of PsA ranges from 6-42% in patients with psoriasis.¹ In majority of patients with psoriasis, arthritis develops after the onset of skin lesions. In about 15%, both skin and joint get affected at the same time and in another 15% the joint involvement precedes the skin involvement. With the recent innovations in the imaging techniques being used in the diagnosis of joint involvement in psoriasis, data show an increasing prevalence of PsA than what it used to be before^{2,3}. It has been observed that peripheral joint disease tends to progress and lead to deformities while central disease has little progression. Similarly patients with oligo arthritis do not develop progressive disease as

those with poly articular involvement. 5% of adults develop PsA in childhood. It is to be noted that at onset half of childhood PsA are monoarticular one fourth are poly articular.⁴ These facts make it important for the clinician to detect patients both children and adults with poly articular disease at an early age. The recent prevalence of PsA in the world population seems to be up to 0.2%.¹ The figures are expected to change in the days to come with the emergence of imaging techniques like USG and MRI, which can detect PsA at an earlier date than the X- ray. These methods detect inflammatory changes in and around joints and entheses even before the clinical symptom or sign could manifest. While conventional X rays reveal the changes much after the onset of clinical symptoms by when considerable tissue damage has already occurred. Furthermore, X- rays are insensitive to the subtle changes like minimal peripheral joint effusion, synovial proliferation and structural abnormalities in tendons or entheses which are radiologic signs of early arthritis. USG allow early identification of joint and periarticular lesions well before destructive changes and the available literature supports the view that USG and MRI have more or less similar efficacy in the diagnosis of PsA.^{5,6} With these background we attempted at correlating the clinical and USG findings in patients diagnosed as PsA, to find the efficacy of USG in picking up changes in the clinically normal joints and or entheses.

MATERIALS AND METHODS

The study group comprised of 12 patients diagnosed as PsA from a total of 228 psoriatic patients treated in the Department of Dermatology, Government Villupuram Medical College and Hospital, Tamil Nadu, India. The symptoms and clinical findings like pain, erythema, warmth, tenderness, swelling, painful joint movement, restricted joint movement were noted in all. Ultra sonogram was done for all these patients using linear transducer with high resolution ranging 7-13 MHz. Wrists, hands, knees, ankle and achilles tendon were scanned on both right and left sides irrespective of the number of clinically involved joints. Ultrasound findings like enthesitis, synovial thickening, effusion, tendon degeneration, bone abnormality, and sclerosis were recorded. These findings were tabulated and analysed.

OBSERVATION AND RESULTS

The age of the study group ranged from 13 years to 62 years. There was equal sex distribution including 6 males and 6 females. 5/12 had psoriasis of skin for more than 5 years; 5 had duration between 1-5 years and in two the duration of psoriasis was less than a year. Except one patient in all others skin involvement preceded joint affection. In one patient both skin and joint manifestation occurred simultaneously. The time interval from the onset of skin disease to joint involvement was ranging from 2-7 years form. There was no metabolic syndrome associated in any of the patients with PsA. Out of the 12 patients, only one female patient had diabetes and one female patient had non cirrhotic portal fibrosis. The number of joints clinically involved is given in table 1.

Table 1: Showing joint involvement on clinical assessment in Patients with PsA

No	Sex/ Age	Hand		Foot		Wrist		Knee		Ankle		T.achillis		Clinically No of joints
		Right	Left	Right	Left	Right	Left	Right	Left	Right	Left	Right	Left	
1	26/M	N	P,S	N	N	N	N	N	N	N	N	N	P,S	2 [Oligo]
2	28/F	P,S	N	N	N	N	N	P,S	N	N	N	N	N	2 [Oligo]
3	42/F	N	N	N	P,S	P,S	N	N	N	N	N	N	N	2 [Oligo]
4	50/M	P,S	N	N	N	N	N	P,S	N	N	N	N	N	2 [Oligo]
5	22/M	N	P,S	N	N	N	N	N	N	N	N	N	N	1 [Oligo]
6	45/F	N	P,S	N	N	N	N	N	P,S	N	N	N	N	2 [Oligo]
7	52/M	N	N	P,S	N	N	N	N	P,S	N	N	N	N	2 [Oligo]
8	50/F	P,S	N	N	N	P,S	N	N	N	N	N	N	N	2 [Oligo]
9	13/F	N	N	N	N	N	N	RM, P	N	N	N	N	N	1 [Oligo]
10	26/M	N	P,S	N	N	N	N	N	N	N	N	N	N	1 [Oligo]
11	62/M	P	P	N	N	P	N	PS,E	P	P	P	S	N	5 [Poly]
12	45/F	P,W	N	N	N	P	N	P	N	N	P	N	N	4 [Poly]

Out of twelve patients, ten had symptoms pertaining to three or less than three joints [oligo arthritis] and two had clinical symptoms involving more than 3 joints [poly arthritis]. The ratio between oligo and polyarthritis clinically was 5:1. Common USG findings observed included synovial thickening, [Fig 1] and joint effusion. Effusion was seen predominantly around the patella. In

one patient there was extension of effusion into the quadriceps muscle [Fig, 2, 3]. Other findings observed were tendon degeneration [Fig 4] and enthesitis [Fig 5]. Enthesitis was found in 7/12 cases and in all seven it was observed in Achilles tendon. Sclerosis was observed in only one patient. Commonly affected joint was interphalangeal joint [Fig 6] accounting for 9/12.

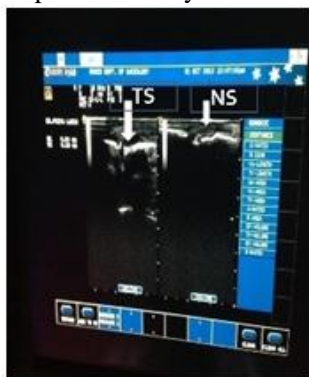

Figure 1

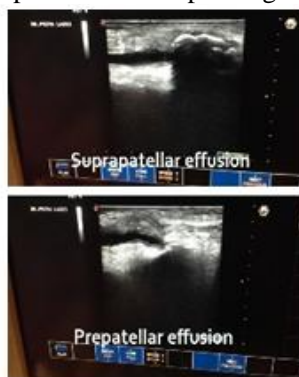


Figure 2

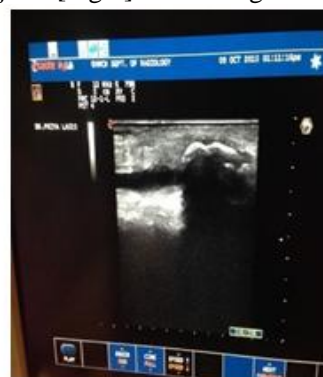

Figure 3

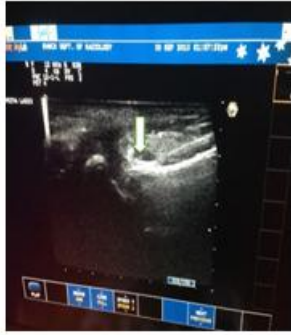

Figure 4

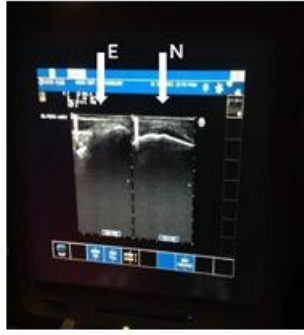

Figure 5

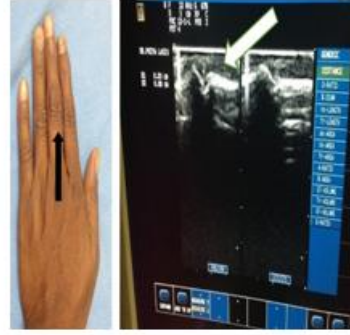

Figure 6

Legend

Figure 1: USG showing synovial thickening at MP joint [TS- Thickened synovium; NS- Normal synovium for comparison]

Figure 2: USG showing supra patellar & pre patellar effusion

Figure 3: USG shows extension of supra patellar effusion into the quadriceps muscle

Figure 4: USG finding showing synovial thickening and tendinous degeneration at wrist joint

Figure 5: USG finding showing Enthesitis involving the Achilles tendon. E- enthesitis; N- normal; for comparison

Figure 6: PIP joint involvement showing Synovial thickening

In 7 out of 12 patients USG showed changes in clinically asymptomatic joints. After USG examination of the patients, it was found that 6/12 showed radiologic changes in more than three joints indicating polyarticular

disease. [Table 2]. Table 2: USG findings in patients with PsA. E: enthesitis; ST: synovial thickening, Eff: effusion, TD: tendon degeneration/ tendinitis; Scl: Sclerosis;

No	Sex / Age	Hand		Foot		Wrist		Knee		Ankle		T.achillis		Clinically No of joints	USG No of joints
		Right	Left	Right	Left	Right	Left	Right	Left	Right	Left	Right	Left		
1	26/M	-	ST, Eff	-	-	-	-	-	-	-	-	TD, E	-	2	2
2	28/F	ST	-	-	-	-	-	ST, Eff	-	-	-	-	-	2	2
3	42/F	-	-	-	ST	ST, Eff	-	-	Eff	-	-	-	E	2	4
4	50/M	ST, Scl	-	-	-	-	-	ST, Eff	ST	-	-	E	-	2	4
5	22/M	-	ST	-	-	-	-	Eff	-	-	-	-	-	1	2
6	45/F	-	ST	-	-	-	-	-	ST, Eff	-	-	-	-	2	2
7	52/M	-	-	ST	-	-	-	ST	ST, Eff	ST	-	E	E	2	5
8	50/F	ST	-	-	-	ST	-	-	Eff	-	-	E	-	2	4
9	13/F	-	-	-	-	-	-	Eff	Eff	-	-	-	-	1	2
10	26/M	-	ST	-	-	-	-	-	-	-	-	-	-	1	1
11	62/M	ST	-	-	-	ST	-	Eff	Eff	ST	ST	TD	TD	5	5
12	45/F	ST	-	-	-	ST	-	Eff	Eff	-	ST	E	E	4	5

Before radiologic assessment the ratio between oligoarthritis and polyarthrits was noted to be 5:1. Whereas, after USG, the ratio between oligoarthritis and polyarthrits was found to be 1:1 [Fig 7], With USG findings 50 % seemed to have more than 3 joints involved. The distribution of different USG findings are given in Figure 8.

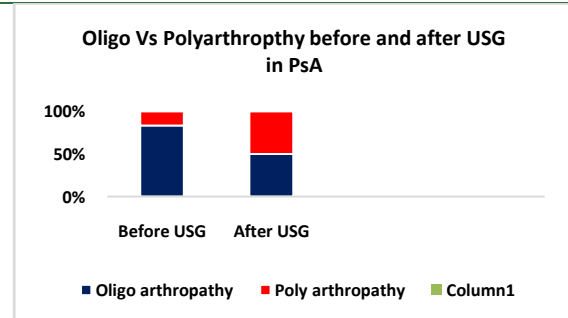


Figure 7: Ratio between oligoarthritis and polyarthrits before and after USG

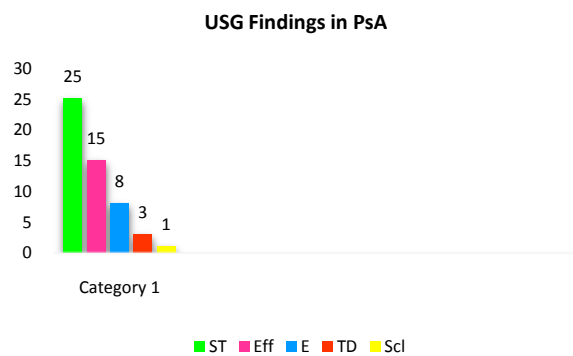


Figure 8: USG findings in patients with PsA. ST: synovial thickening, Eff: effusion,

E: enthesitis; TD: tendon degeneration/ tendinitis; Scl: Sclerosis. In our study synovial thickening was found to be the commonest US finding followed by joint effusion.

DISCUSSION

PsA has a wide spectrum of clinical manifestation owing to the different targets of inflammation that may include the entheses, synovial sheaths, peripheral joints, axial skeleton, which can be involved in isolation or in combination. The diverse pattern of clinical presentation includes peripheral disease like distal interpalangeal arthritis, dactylitis, enthesitis, synovitis and axial disease that includes sacroiliitis and spondylitis. The severity of joint involvement may range from mild non-destructive pathology to severe mutilating problem leading to a rapidly destructive arthropathy. Clinical symptoms of PsA may include:

- Swelling over region of the affected joints or even the entire digit
- Pain and tenderness in the joints
- Difficulty in moving the joints or morning stiffness lasting more than 30 minutes.
- Deformity and crippling of the severely affected joints

Early Diagnosis of PsA helps to initiate treatment in the early phases of inflammation and aims at modifying the natural course of the disease which is progressive and destructive. With the advent of newer drugs like anti-tumour necrosis factor agents, an early diagnosis of PsA has now become a challenging mission for the treating physician. In order to rule in patients with features of PsA before subjecting them for investigations, it is advisable to follow standard criteria for screening. The original diagnostic criteria of Moll and Wright are the simplest and the most frequently used. The Classification Criteria for Psoriatic Arthritis (CASPAR) has 98.7% sensitivity and 91.4% specificity.⁷ Psoriatic arthritis screening and

evaluation [PASE] questionnaire fulfils many properties of an effective screening tool which is brief and self-administered.^[8] All these criteria serve only as a screening tool for PsA and does not substitute for a thorough examination or investigation to confirm or assess the disease. It is important to understand that in children with PsA, there seems to be a biphasic age of onset, with peaks occurring at approximately 2 years of age and again in late childhood. Younger children are more likely to be females and exhibit dactylitis and small joint involvement, with an increased tendency to progress to polyarticular disease. Whereas older children tend to manifest enthesitis, axial joint disease, and persistent oligoarthritis. It is to be remembered that despite a higher utilization of methotrexate therapy, younger patients may need longer duration of treatment to achieve clinical remission and hence the need for early diagnosis and appropriate treatment.⁹ Observations made in different studies indicate a relentlessly progressive nature of the disease at least in some patients, despite treatment. In up to 47% of patients joint damage occurs within two years of onset; up to 20% develop a severely destructive, disabling form of arthritis. Studies have documented, certain predictors both clinical and radiological to assess the disease progression in PsA.^[10,11] With time oligo articular joint involvement may become poly articular and PsA is said to be associated with reduced life expectancy. The above observations explicitly indicate the progressive nature of PsA. Regarding radiological diagnosis of PsA, width of the joint space was considered as a common parameter in the assessment of arthritis. The newer imaging techniques have made no significant improvement in the evaluation of joint space width. However, it has to be remembered that narrowing of joint space is a late manifestation.^[12] Conventional radiography can detect destructive lesions after many months or years of damage. There is definitely higher sensitivity of USG and MRI over conventional radiography. Many studies consider MRI to be slightly superior to USG in early detection of PsA. Using advanced technology, USG seems as good as MRI in detecting the inflammatory changes in the joints, entheses and peri articular tissues. There are many studies in the literature pertaining to the usefulness of USG in the early diagnosis of PsA. The observations differ from different canters. The specifications of the US machine used, the expertise of the radiologists performing the test also contribute to the variations in the findings observed. In a Cross sectional study performed by Lin et al, in the PsA group, using high frequency ultrasound, 60.9 % showed joint effusion.^[13] Whereas in our study joint effusion was observed in 11/12 patients. Gutierrez et al have shown that the most affected entheses was the Achilles entheses,

followed by distal patellar and proximal patellar entheses.^{14,15}. Our observations also show that Achilles tendon is the commonest entheses involved radiologically. Thus far, there is enough evidence supporting the validity of USG in the assessment of entheses which is not picked up by conventional X-ray. We attempted to correlate clinical and radiological findings and found it very useful in detecting inflammation in the clinically asymptomatic joints at an earlier date. What presented as an oligo arthritis clinically, turned out to be a polyarticular disease after USG findings in 6/12 patients. Such classification of PsA has a major impact on predicting the disease progression and hence on the treatment protocol. In our study synovial thickening was the most frequent finding followed by effusion. Our observational data clearly point that USG is a very useful tool in the diagnosis of inflammatory joint diseases like PsA. It was also observed in many studies that there is regression of synovial effusion following treatment which was confirmed by the correlation of synovial fluid biomarkers can be considered as a reliable indicator of therapeutic response.^{16, 17} For the physician, the crucial factor influencing the effectiveness of therapy lies in the time of initiation of treatment. In other words, the administration of specific drug should be started much before the onset of irreversible damage. It is also known that in PsA, polyarthritic onsets progressive in nature and can lead on to mutilation. Destructive pathology in the joints resulting in mutilation lead to a significant deterioration of quality of life in the patient. This also leads to inability to perform job, incur more expense and as consequence may even result in social exclusion. Taking into consideration the ease of availability and the cost, USG is definitely far superior to MRI in the detection of PsA. With newer advancements in the techniques, USG may soon find its place in every psoriasis clinic. With invent of modern therapeutic agents like biological therapy, drugs started at an early stage can certainly reduce the on-going inflammatory process and can even reverse the pathology. This in other words may give a clue that, those diagnosed as polyarthropathy using imaging techniques, can be benefitted by biologics. Many authors are also of the view that routine use of USG is valuable in the early diagnosis, treatment and follow up of patients with PsA.^{18, 19, 20}

CONCLUSION

USG show macroscopic inflammatory lesions of joints even before clinical symptoms and allow the assessment of soft tissues well ahead of the bone damage revealed by conventional radiography. Early detection of PsA using USG brings in better scope for early implementation of

appropriate drugs which can prevent joint destruction or at least substantially delay the damage. USG which is more sensitive than X ray and much cheaper than MRI should be considered in all patients with clinical suspension of PsA.

REFERENCES

1. Zochling J and Smith EU. Seronegative spondyloarthritis. *Best Pract Res Clin Rheumatol.* 2010; 24(6):747-56.
2. Mease PJ. Tumour necrosis factor (TNF) in psoriatic arthritis: pathophysiology and treatment with TNF inhibitors. *Ann Rheum Dis.* 2002; 61:298-304.
3. McQueen FM. MRI in Psoriatic Arthritis. *Ann Reum Dis.* 2007; 66(2):19.
4. Kumar A and Grover R. Management of psoriatic arthritis. *J Indian Rheumatol Assoc* 2002 : 10 : 64 – 68
5. Laura C, Richard H, Conaghan Philip G, Freeston Jane E. MRI and ultrasonography for diagnosis and monitoring of psoriatic arthritis. *Best practice & research. Clinical rheumatology* 2012; 26 (6): 805-22.
6. Sankowski AJ, Lebrowska UM, Cwikła J, Walecka I and Walecki J. The comparison of efficacy of different imaging techniques (conventional radiography, ultrasonography, magnetic resonance) in assessment of wrist joints and metacarpophalangeal joints in patients with psoriatic arthritis. *Pol J Radiol.* 2013; 78(1): 18-29.
7. Ross E Petty, Taunton R Southwood, Prudence Manners, John Baum, David N Glass, Jose Goldenberg, Xiaohu He et al. International League of Associations for Rheumatology Classification of Juvenile Idiopathic Arthritis: Second Revision, Edmonton, 2001. *J Rheumatol.* 2004; 31: 390-392.
8. Abby Van Voorhees, Steven R. Feldman, John Y. M. Koo, Mark G. Lebwohl, Alan Menter, *Psoriasis and Psoriatic Arthritis Pocket Guide: Treatment Algorithms and Management Options.* Third edition. Chapter 2 page 30-37.
9. Stoll ML, Zurakowski, D, Nigrovic, LE, Nichols DP, Sundel RP and Nigrovic, PA. Patients with juvenile psoriatic arthritis comprise two distinct populations. *Arthritis & Rheumatism.* 2006; 54: 3564-3572.
10. Gladman DD, Farewell VT. Progression in psoriatic arthritis: role of time varying clinical indicators. *J Rheumatol.* 1999;26(11):2409-13
11. Gladman D, Mease PJ, Choy E HS, et al. Analysis of risk factors for radiographic progression in psoriatic arthritis (PsA): subanalysis of ADEPT. Program and abstracts of the American College of Rheumatology (ACR) 71st Annual Meeting; November 6-11, 2007; Boston, Massachusetts. [Abstract #583]
12. Keat A. ABC of Rheumatology: Spondyloarthropathies. *BMJ.* 1995; 310:1321-24.
13. Lin Z, Wang Y, Mei Y, Zhao Y, Zhang Z. High-frequency ultrasound in the evaluation of psoriatic arthritis: a clinical study. 2016; *Am J Med Sci* 350:42-46
14. Frediani B, Falsetti P, Storri L, Allegri A, Bisogno S, Baldi F, Marcolongo R. Ultrasound and clinical evaluation of quadriceps tendon enthesitis in patients with psoriatic arthritis and rheumatoid arthritis. *Clin Rheumatol.* 2002; 21:294-298.]

15. Gutierrez M, Draghessi A, Bertolazzi C Erre GL, Saldarriaga-Riveral LM, López-Reyesl A et al Ultrasound in psoriatic arthritis. Can it facilitate a best routine practice in the diagnosis and management of psoriatic arthritis? Clin Rheumatol published online 08/2016; DOI: 10.1007/s10067-015-3053-4.
16. Fiocco U, Sfriso P, Oliviero F, Roux-Lombard P, Scagliori E, Cozzi L, Lunardi F e al Synovial effusion and synovial fluid biomarkers in psoriatic arthritis to assess intra articular tumor necrosis factor- α blockade in the knee joint. Arthritis Res Ther. 2010; 12(4): R148.
17. Husic R, Ficjan A, and Duftner C, Dejacó C. Use of ultrasound for diagnosis and follow-up of psoriatic arthritis. EMJ Rheumatol. 2014; 1:65-72.
18. De Filippis LG, Caliri A, Lo Gullo R, Bartolone S, Miceli G, Cannavò SP, et al. Ultrasonography in the early diagnosis of psoriasis-associated enthesopathy. Int J Tissue React. 2005; 27(4):159-62.
19. Kane D. The role of ultrasound in the diagnosis and management of psoriatic arthritis. Curr Rheumatol Rep. 2005;7(4):319-24.
20. De Simone C, Caldarola G, D'Agostino M, Carbone A, Guerriero C, Bonomo L et al. Usefulness of Ultrasound Imaging in Detecting Psoriatic Arthritis of Fingers and Toes in Patients with Psoriasis. Clinical and
21. Developmental Immunology. 2011, Article ID390726, 5 pages available at <http://dx.doi.org/10.1155/2011/390726>

Source of Support: None Declared
Conflict of Interest: None Declared