

# Magnetic resonance imaging diagnosis of Mayer-Rokitansky-Kuster-Hauser syndrome

Shaurya Thakran<sup>1\*</sup>, Hemant Mishra<sup>2</sup>, Sunilagrwal<sup>3</sup>, Ravindrakumar<sup>4</sup>

<sup>1</sup>Resident, <sup>2</sup>Professor and HOD, <sup>3,4</sup>Professor, Department of Radio diagnosis, Mahatma Gandhi Medical College and Hospital, Sitapura, Jaipur, Rajasthan, INDIA.

Email: [drshaurya21@gmail.com](mailto:drshaurya21@gmail.com)

## Abstract

Mayer-Rokitansky-Kuster-Hauser (MRKH) syndrome is an uncommon variation in the prenatal development of the female genital tract. It is a congenital malformation of the female genital tract. Its features include partial or complete absence (agenesis) of the uterus with an absent or hypoplastic vagina normal fallopian tubes, ovaries, normal external genitalia and the typical 46, XX, female chromosome pattern. Breast development and growth of pubic hair are also normal. Associated renal and/or skeletal abnormalities are common. Mayer-Rokitansky-Kuster-Hauser syndrome is also known as Mullerian Agenesis. The incidence is one in 4000–5000 female births<sup>1,2</sup>. The normal external appearance of MRKH females makes it difficult to diagnose until puberty, typically diagnosed in mid-adolescence. The average age of diagnosis is between 15 and 18 years, although occasionally a girl may be diagnosed at birth or during childhood because of other health problems. A pelvic ultrasound may be used to see the presence or absence of the uterus and its condition.

**Keywords:** MRKHS, MRI, USG.

## \*Address for Correspondence:

Dr. Shaurya Thakran, Resident, Department of Radio diagnosis, Mahatma Gandhi Medical College and Hospital, Sitapura, Jaipur, Rajasthan,

Email: [drshaurya21@gmail.com](mailto:drshaurya21@gmail.com)

Received Date: 25/08/2016 Revised Date: 12/09/2016 Accepted Date: 02/10/2016

## Access this article online

Quick Response Code:



Website:

[www.statperson.com](http://www.statperson.com)

Volume 6  
Issue 4

## CASE REPORT

A 24-year-old female presented with primary amenorrhea. On examination, the patient's secondary sexual characteristics were found to be normal. She has normal breast development, average height and weight, and normal arm span. The patient also has normal body hair distribution, including pubic and axillary hair. Pelvic examination showed normally estrogenized vulva, labia minora and majora, and clitoris. An ultrasound scan of the abdomen and pelvis was done on GE Voluson S6 using 3.5-5MHz frequency transducer [figure 5-6] revealed a poorly formed uterus. Right ovary was normal in size and appearance. A single right kidney was found with mild

dilatation of pelvicalyceal system seen with mild hydronephrosis, left kidney was not visualized in left renal fossa and usual ectopic locations. An MRI of the pelvis was then performed by GE MRI 1.5 T real time scanner [Figures 1-4]. The sagittal T2 W MRI image [figure 1] demonstrated hypoplastic uterus and cervix. The axial T2W axial image [Figure 2] confirmed absent / hypoplastic cervix and absence of vagina between the rectum and bladder. The STIR T2W axial images [figure 3] shows presence of normal right ovary with follicles. The Coronal T2W images [figure 4] confirmed an enlarged single right kidney with mild hydronephrosis, and mild dilatation of proximal ureter with absent left kidney. Hormone profile included measurement of follicular stimulating hormone (FSH), luteinizing hormone (LH), estradiol which were all normal, indicating normal hypothalamic-pituitary-ovarian axis.

Table 1:

Test name	Patient range	Normal range
FSH	7.64 mIU/ml	2.5 – 9.1 (reproductive age)
LH	3.36 mIU/ml	1.9 – 16.9 (reproductive age)
ESTRADIOL	228.01 pg/ml	within normal limits
TSH	3.93 uIU/ml	0.3 – 5.5 (adult >20 yrs.)

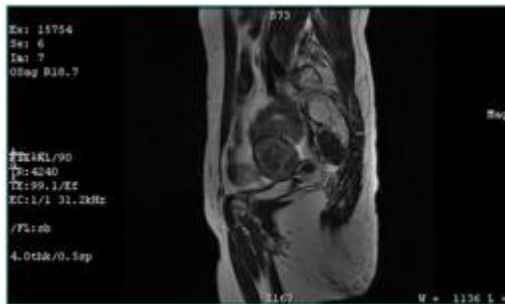


Figure 1:

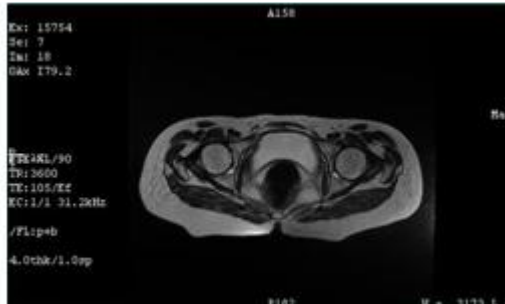


Figure 2

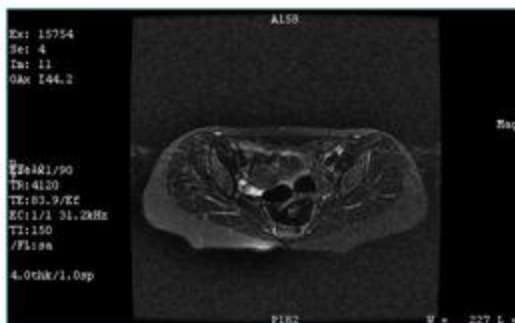


Figure 3

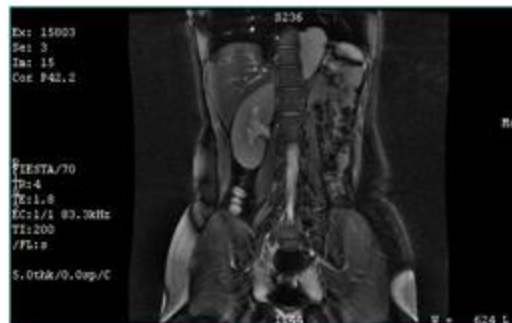

Figure 4

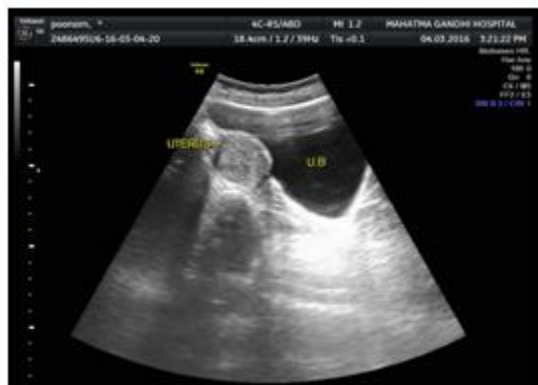

Figure 5

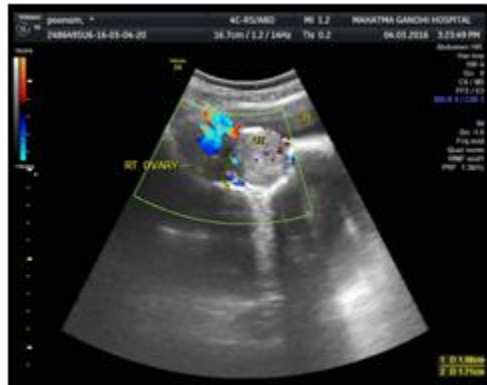

Figure 6

**Figure 1:** Sagittal T2W image in mid sagittal plane. Uterus appearing hyperintense can be made out with normal contour but small / rudimentary body and cervix.

**Figure 2:** Axial T2W image at the level acetabulum showing absent vagina between the bladder and rectum

**Figure 3:** Axial STIR image at a higher level demonstrates normal right ovary with follicles, left ovary was not visualized.

**Figure 4:** Coronal T2W –showed an enlarged single right kidney with mild hydronephrosis, absent left kidney.

**Figure 5:** USG sagittal plane image showing poorly formed uterus, cervix was not clearly visualized.

**Figure 6:** USG transverse plane image shows normal right ovary, left ovary was not visualized.

## DISCUSSION

Uterine malformations occur in about 0.1–0.5% of all women.<sup>7</sup> Mayer-Rokitansky-Kuster-Hauser (MRKH) syndrome is a rare developmental failure of a part or whole of the Mullerian duct resulting in congenital absence of uterus and vagina with a prevalence of 1 in 4000–5000 female births. It accounts for approximately 15% of patients with primary amenorrhea and is also the second commonest cause. Genetic tests indicated normal (46, XX) female karyotype, which, obviously, is what

differentiates MRKH syndrome from other genital tract development defects such as Turner syndrome (45,0X) and androgen insensitivity syndrome (46, XY)<sup>3</sup>. Some authors classify the syndrome in 2 types: type I is characterized by an isolated absence of the upper two thirds of the vagina; type II is associated with other malformations. Upper urinary tract malformations are found in about 40% of cases,<sup>1</sup> including unilateral renal agenesis (23%-28%), ectopia of one or both kidneys (17%), renal hypoplasia (4%), and horseshoe kidney and

hydronephrosis. Skeletal abnormalities are found in 10%, while auditory defects are found in 2% to 10% of cases.<sup>4,5,6</sup> The syndrome was first described by Mayer in 1829. Initial description consisted of various vaginal anomalies like duplications due to abnormal development of the Mullerian ducts. Later in 1838, Rokitansky described uterine and vaginal agenesis. Kuster recognized renal abnormalities, such as renal ectopy or agenesis as well as skeletal abnormalities in 1910. Other rare associations are cardiac anomalies and anorectal malformations (ARM). Hauser distinguished MRKH from testicular feminization in 1961. The diagnosis is frequently made clinically, but often confirmed either radiologically or laparoscopically in patients whose hormonal and karyotypic investigations for primary amenorrhea are normal. Two-dimensional ultrasound is the initial choice of diagnostic modality, but three-dimensional ultrasound maybe more sensitive. When ultrasound is equivocal, computed tomography (CT) can detect and differentiate congenital anomalies, but it is not routinely performed due to ionizing radiations. An MRI can be more effective owing to its multiplanar capability and the best soft tissue contrast compared to any other imaging modality, without the use of ionizing radiations.<sup>7</sup> Uterine agenesis or hypoplasia is best diagnosed on T2 weighted sagittal images. The slice thickness should be 5 mm or less. Uterine hypoplasia may be diagnosed when there is small uterus and reduced intercornual distance (< 2 cm), but the patients may also have poor zonal differentiation and reduced endometrial and myometrial widths.<sup>7,8</sup> The endometrial cavity and the myometrium may be reduced in size. An endometrial segment may demonstrate increased signal intensity and be expanded depending on the presence of obstruction. An MRI has the ability to differentiate normal and abnormal uterus due to its exquisite soft tissue contrast resolution. Vaginal agenesis is best characterized on axial planes with no normal vaginal anatomy identified between the rectum and urethra. Its multiplanar capabilities are useful in the overall evaluation of the female pelvis, particularly when complex anorectal anomalies are expected. The normal ovaries can be well demonstrated with MRI where normal follicles can be identified. Normal ovaries are the major factors in the diagnosis of MRKH syndrome. The coronal MRI also helps to identify any associated renal malformations. The clinical findings of MRKH syndrome are remarkable and a clinical diagnosis can be easily established. However, confirmation of the diagnosis, evaluating for other associated anomalies and sometimes to rule out a coexistent Turner's syndrome need further investigations including laparoscopy, imaging and karyotyping. The classical case of MRKH syndrome, where the vagina is completely absent from the introitus,

accounts for nearly 95% of all cases. The clinical diagnosis and surgical planning may relatively be simple. However, in the remaining 5% of patients, a blind upper one-third of the vagina can be present which cannot be satisfactorily evaluated by laparoscopy or ultrasound (2D or 3D). Our patient had a similar appearance. An MRI can definitely be more accurate and comprehensive in the evaluation of such patients. The congenital anomalies of the upper renal tracts can be associated in as many as 30–40% of the patients. The common types of renal anomalies may include renal agenesis and ectopic pelvic kidney<sup>9-12</sup>. When a coexistent renal anomaly is present, particularly an ectopic kidney in the pelvis or a horseshoe kidney where it is usually low placed; a laparoscopy may not be able to evaluate the abnormal position of the kidney, which is of significance during surgical management like vaginoplasty. An ultrasound examination will be able to identify these patients consistently, although, sometimes it may be difficult to visualize if bowel loops obscure the kidney or if the kidney is hypoplastic/aplastic. A CT scan is effective in evaluating such patients but at the cost of exposing the patient to ionizing radiations. When there are associated anorectal anomalies, an MRI can be invaluable in comparison with any other modality of investigation. Therefore, we conclude that MRI is the mainstay of imaging evaluation of MRKH syndrome, not only to confirm clinically diagnosed Mullerian anomalies of uterus but also to assess the degree of vaginal dysgenesis and associated anomalies like ARM and renal anomalies, which have an impact on the planning of treatment. With more sophisticated MR technology and availability of pelvic phase array coils, MRI is better equipped to evaluate these patients noninvasively. Though the cost and availability of MRI maybe a limiting factor, particularly in India, its very high soft tissue resolution, multiplanar capability and noninvasive but versatile nature makes MRI to be considered as a comprehensive package for the evaluation of these patients. We presume MRI can replace laparoscopy, particularly before planning surgery due to its noninvasive nature providing equally sufficient, if not more, information. An accurate diagnosis of MRKH is important as the patient can actually conceive and have their reproductive function fulfilled with the help of surrogate uterus.

## REFERENCES

1. Morcel K, Camborieux L. Mayer-Rokitansky-Kuster-Hauser (MRKH) syndrome. *Orphanet J Rare Dis.* 2007; 2:13.
2. Sultan C, Biason-Lauber A, Philibert P. Mayer-Rokitansky-Kuster-Hauser syndrome: recent clinical and genetic findings. *GynecolEndocrinol.* 2009; 25:8-11.

3. Sem KK, Kapoor A. Mayer-Rokitansky-Kuster-Hauser syndrome. *Ind J Radiol Imag.* 2006; 16: 805-7
4. Gupta NP, Ansari MS. Mayer-Rokitansky-Kuster-Hauser (MRKH) syndrome—a review. *Indian J Urol.* 2002; 18:111-116.
5. Morcel K, Camborieux L. Programme de Recherchessur les AplasiesMulleriennes (PRAM), Daniel Guerrier, Mayer-Rokitansky-Küster-Hauser (MRKH) syndrome. *Orphanet J Rare Dis.* 2007; 2:13.
6. Pittock ST, Babovic-Vuksanovic D, Lteif A. Mayer-Rokitansky-Kuster-Hauser anomaly and its associated malformations. *Am J Med Genet A.* 2005; 135: 314-316.
7. Siegel MJ. Pediatric applications. In: Lee JK, editor. Chapter 24 of computed body tomography with MRI correlation. 3rd ed. 1998. p. 1548.
8. Saleem SN. MR imaging diagnosis of utero vaginal anomalies: Current state of art. *Radiographics.*2003; 23:e13.
9. Chervenak FA, Stangel JJ, Nemeč M, Amin HK. Mayer RokitanskyKuster Hauser syndrome. *N Y State J Med.* 1982; 82:23–6
10. Evans TN, Poland ML, Boving RL. Vaginal malformations. *Am J ObstetGynaecol.* 1961; 141:910–20.
11. Griffin JE, Edwards C, Madden JD, Harrod M, Wilson JD. Congenital absence of the vagina, the Mayer RokitanskyKuster Hauser syndrome. *Ann Intern Med.* 1976; 85:224–36.
12. Bryan A, Nigro J, Counsellor VS. One hundred cases of congenital absence of the vagina. *SurgGynecol Obstet.* 1949; 88:79–86.

Source of Support: None Declared  
Conflict of Interest: None Declared