

# Category wise occurrence of breast lesions according to BIRADS mammography lexicon: An observational study

Megha Wani<sup>1\*</sup>, Rajashree Purohit<sup>2</sup>

<sup>1</sup>Consultant Radiologist, <sup>2</sup>Consultant General and Breast Surgeon, Dr. Hedgewar Hospital, Aurangabad-431001, Maharashtra, INDIA.

Email: [meghagumte@gmail.com](mailto:meghagumte@gmail.com)

## Abstract

**Objective:** To study category wise occurrence of breast lesions according to BIRADS mammography lexicon. To calculate age group wise occurrence of each category. To assess usefulness of this lexicon to reduce the rate of unnecessary biopsies and histopathological examination. **Materials and Methods:** This is observational study of 2763 patients in age group of 20 to 80 years. Mammography findings were classified into various categories according to BIRADS mammography lexicon. Occurrence of each category and age wise distribution of each category done. **Results:** Majority of patients were found in 31 to 40 years age group. BIRADS category I is found to be commonest category followed by BIRADS category II. BIRADS category I and II are commonly seen in 31 to 40 years age group. Potentially malignant lesions that is BIRADS Category IV and V were found commonest in 31 to 50 years of age group. **Conclusion:** Commonest category of breast lesions is BIRADS category I and II. Categorising the lesion in these two categories defers the clinician from doing biopsies and histopathological examination. Category 4 and 5 are seen to be more common in younger patients in addition to older population.

**Key Words:** Breast, malignancy, mammography, sonomammography.

## \*Address for Correspondence:

Dr. Megha Wani, Consultant Radiologist, Dr. Hedgewar Hospital, Aurangabad-431001, Maharashtra, INDIA.

Email: [meghagumte@gmail.com](mailto:meghagumte@gmail.com)

Received Date: 19/05/2017 Revised Date: 12/06/2017 Accepted Date: 08/07/2017

Access this article online	
Quick Response Code:	Website: <a href="http://www.medpulse.in">www.medpulse.in</a>
	Volume 7 Issue 3

## INTRODUCTION

Patients studied in the present study are from rural area of Marathwada region of state of Maharashtra, as Dr. Hedgewar hospital at Aurangabad, caters to the rural population of this region. Few words about breast pathologies and their presentations. Breast pathologies have variety of etiologies, benign and malignant. Common benign lesions are fibroadenoma, cysts, abscess, galactocele, seroma, hematoma, liponecrosis, hemangioma, phylloids tumour, hamartoma, papilloma, inflammatory, infectious and reactive disorders, intramammary lymph nodes etc. Fibroadenoma is the most common benign breast mass; Invasive ductal

carcinoma is most common malignancy<sup>1</sup>. A palpable breast mass, either self-detected or found at clinical breast examination, is a common presenting symptom in women. Although most lumps ultimately are found to be benign, a palpable lump can cause understandable anxiety for the patient and lead to repeated clinical and imaging evaluation, biopsy, and surgery. Given that a palpable breast mass is the most common symptom associated with breast cancer.<sup>2</sup> Breast cancer is the most common type of cancer and second most common cause of death from cancer in women<sup>3</sup>. A woman's chance of developing invasive breast cancer at some time in her life is approximately 1 in 8 (12%)<sup>4</sup>. Breast cancer commonly affects women older than 40 years of age; however, younger women can also be affected, especially those with a genetic predisposition<sup>5</sup>. Because many breast masses may not exhibit distinctive physical findings, imaging evaluation is necessary in almost all cases to characterize the palpable lesion<sup>6</sup>. Women who presented with breast symptoms or who have palpable findings on clinical examination are usually investigated with breast imaging which generally consist of mammography or sonography or both<sup>7</sup>. Mammography is the most specific and sensitive method for diagnosis of breast cancer at its earliest presentation<sup>8</sup>. Mammography is also considered

gold standard as screening procedure to visualize micro calcifications which are hallmark of malignancy. Sonography plays a key role in differentiating cystic and solid masses<sup>9</sup>. Radiologist analyses the patient and images and describes the findings regarding the probable nature of lesion. The reporting terminology and pattern defers from one radiologist to another. The interpretation of report by concerned clinician again defers. The Breast Imaging Reporting and Data System (BI-RADS) initiative, instituted by the ACR, was begun in the late 1980s to address a lack of standardisation and uniformity in mammography practice reporting. An important component of the BI-RADS initiative is the lexicon, a dictionary of descriptors of specific imaging features. The BI-RADS lexicon has always been data driven, using descriptors that previously has been shown in the literature to be predictive of benign and malignant disease<sup>10</sup>. The ACR BI-RADS is a quality assurance tool designed to standardize reporting, reduce confusion in breast imaging interpretations and management recommendations, and facilitate outcome monitoring<sup>11</sup>. This system was developed to bring uniformity in reporting system all over world and to develop common understanding of the reports by the clinician and radiologists. Classification of lesions according to BI-RADS category has enabled more consistent assessment and management of breast lesions. The subsequent result was that clinician has clear idea about which lesions to be biopsied and which are simply followed up. Each

mammographic study should be assigned a single assessment based on the most concerning findings<sup>12</sup>. Not only does this facilitates clear, concise and standardised reporting but it also permits simultaneous data collection for maintenance of database used for future outcomes review<sup>13</sup>. Use of approved terminology is key to the production of understandable breast imaging report. The BI-RADS approach to reporting mammography examination categorizes the overall composition of the breast and then describes noncalcified lesion by their basic shape, border, characteristics and density. Calcifications are described according to size, morphology and distribution. The findings are then evaluated and an assessment is rendered that includes degree of suspicion for malignancy. Finally the report indicates the pertinent management recommendations. BI-RADS assessment categories are numbered from 0 to VI. Given that BI-RADS can impact on patient care by minimizing both overutilization and underutilization of follow-up tests/procedures, it is critical that family physicians, and other clinicians providing care to women, be familiar with the interpretation of and management strategy for each category<sup>15</sup>. BI-RADS in general and the lexicon specifically were not intended to be static. After the initial creation of BI-RADS in 1993, 3 more editions were created in 1995, 1998, and 2003<sup>16</sup>. Now the Recent edition is of 2013. BI-RADS CATEGORY radiological images.

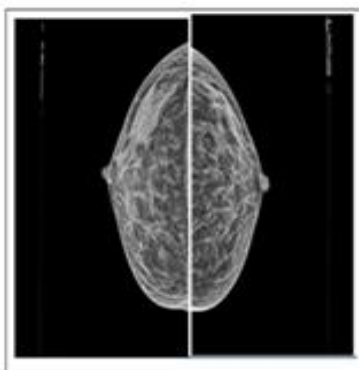


Figure 1: Birads category I

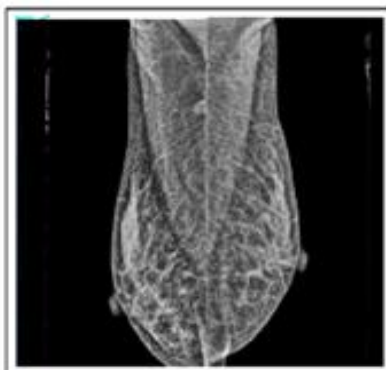

Figure 2: BIRADS CATEGORY II

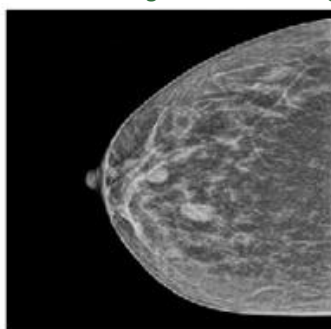
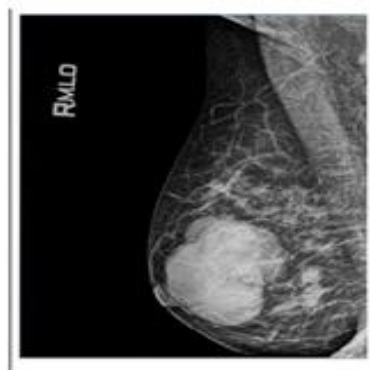


Figure 3: Birds category III

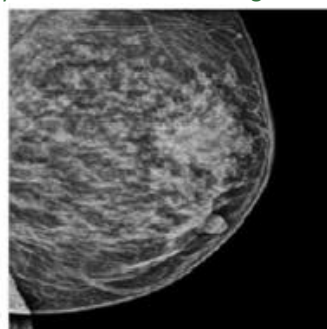


Figure 4: BIRADS CATEGORY IV;

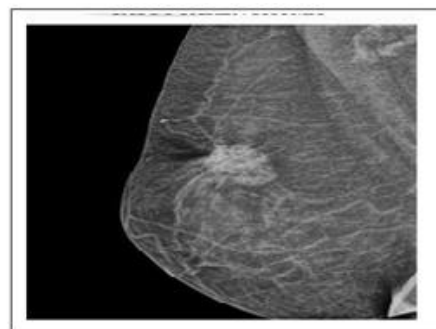


Figure 5: BIRADS CATEGORY V

**MATERIAL AND METHODS**

Patients studied in the present study are from rural area of Marathwada region presenting at Dr. Hedgewar hospital with various breast symptoms for mammography. Institutional ethical committee approval was obtained for this observational study. Mammography and sonomammography records of 2763 patients, from June 2008 to December 2014, were reviewed for present study. The age of patients in study population is from 20 to 80 years with mean age of study being 31-40 years. Mammography was done on GE DMR PLUS

mammography machine. Standard craniocaudal and mediolateral oblique views were taken. Patients with BIRADS category II lesions were evaluated by sonography additionally to know cystic and solid nature of lesion. Sonomammography was done on Toshiba xario Colour Doppler machine using 10-12 MHZ probe. Image interpretation was done by radiologist experienced in mammography. Radiologist analyses the patient and images and describes the findings regarding the nature of lesion according to that mentioned in lexicon.

**Table 1**

Mammography lexicon			
Breast Composition	A entirely fatty B Scattered areas of fibroglandular density. C Heterogenously dense, which may obscure masses. D Extremely dense which lowers sensitivity		
Mass	Shape		Oval-round-irregular
	Margin		Circumscribed- obscuredmicrolobulatedindistinctspiculated
	Density		Fat-low-equal-high
Asymmetry	Asymmetry-global-foal-developing		
Architectural distortion	Distorted parenchyma with no visible mass		
Architectural Distortion	Distorted parenchyma with no visible mass		
Calcifications	Morphology	Suspicious	Typically benign
			1 Amorphous 2 Coarse heterogeneous 3 Fine pleomorphic 4 Fine linear or fine linear branching
	Distribution		Diffuse-regional-grouped- linearsegmental
Associated features	Skin retraction-nipple retraction-skin thickening –trabecular thickening –axillary adenopathy- architectural distortioncalcifications.		

**Table 2:** Lesions then assigned category as that mentioned in BIRADS mammography lexicon

Final Assessment Categories			
	Category	Management	Likelihood of cancer
0	Need additional imaging or prior examinations	Recall for additional imaging and /or await prior examinations.	n/a
1	Negative	Routine screening	Essentially 0%
2	Benign	Routine screening	Essentially 0%
3	Probably benign	Short interval- follow- up (6 month) or continued	>0% but ≤ 2%
4	Suspicious	Tissue diagnosis	4a. low suspicion for malignancy (>2% to ≤ 10%) 4b. moderate suspicion for malignancy (>10% to ≤ 50%) 4c. high suspicion for malignancy (>50% to <95%)
5	Highly suggestive of malignancy	Tissue diagnosis	≥ 95%
6	Known biopsy- proven	Surgical excision when clinical appropriate	n/a

Category 0 lesions were not reported because additional imaging requirements as well as clinical details were taken care off at the time of examination.

Histopathologically proven cases were not referred so no category VI reports were found. Normal mammography classified as BI-RADS category I. BI-RADS category II

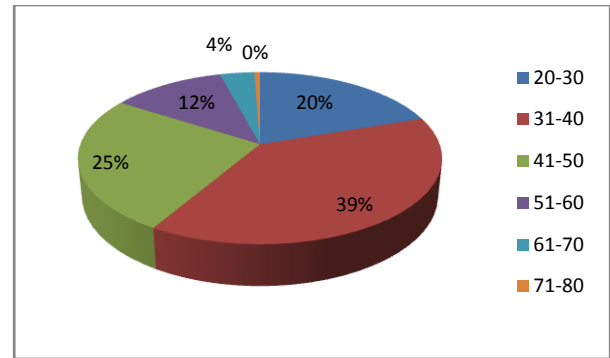
lesions are lesions which are definitely benign. Like category I, this is a normal assessment, but here the interpreter chooses to describe a benign finding in the mammography report. Fibroadenomas, simple cysts, abscesses and multiple dilated ducts were classified as category II. Involuting calcified fibroadenomas, skin calcifications, metallic foreign bodies (such as core biopsy and surgical clips), and fat-containing lesions (such as oil cysts, lipomas, galactoceles, and mixed-density hamartomas) all have characteristically benign appearances and may be described with confidence. The interpreter may also choose to describe intramammary lymph nodes, vascular calcification, implants, or architectural distortion clearly related to prior surgery while still concluding that there is no mammographic evidence of malignancy.<sup>17</sup> The lesions where the radiologist is not sure about benign nature of lesion are categorized under category III. A finding assessed using this category should have a  $\leq 2\%$  likelihood of malignancy, but greater than the essentially 0% likelihood of malignancy of a characteristically benign finding. Three specific findings are validated as being probably benign, noncalcified circumscribed solid mass, focal asymmetry, and solitary group of punctate calcifications<sup>18</sup>. These lesions were advised follow up after 6 months. Category IV lesions included the lesions which are more likely to be malignant. This category is reserved for findings that do not have the classic appearance of malignancy but are sufficiently suspicious to justify a recommendation for biopsy.<sup>19</sup> Any solid or cystic lesion which appears to have mammographic features suggestive of malignancy are included in this category. Single dilated duct with suspicious lesion is also categorized under category IV. Category V lesions were such lesions which are definitely malignant. These assessments carry a very high probability ( $\geq 95\%$ ) of malignancy<sup>20</sup>. Biopsy in these cases is mandatory.

## RESULTS

**Table 3:** Age wise distribution

AGE	NUMBER
20-30	547
31-40	1070
41-50	705
51-60	326
61-70	99
71-80	16
<b>Total</b>	<b>2763</b>

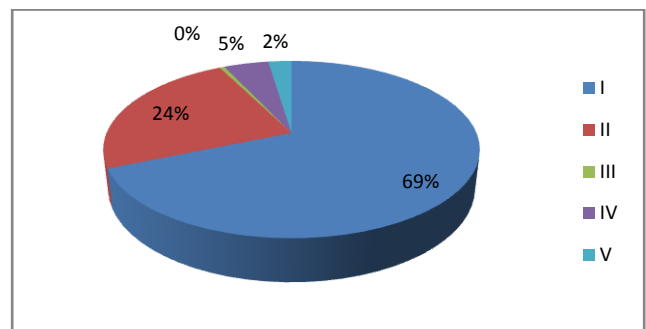
In our study the most commonly seen age group is 31-40 years.



**Figure 5:** Age wise distribution

**Table 4:** Lesion wise distribution

LESION	Number	percentage
I	1898	68.69%
II :	658	23.81%
III	14	00.50%
IV	127	04.59%
V	66	02.38%
<b>Total</b>	<b>2763</b>	



**Figure 6:** Lesion wise distribution

In the present study most commonly seen lesion was category I. 68.69% of patients were in this category. BIRADS category II patients are found in 23.8 % of patients. BIRADS category III lesions found in 0.50 % of patients and is seen in least number of patients.

**Table 5:** Agewise distribution of category I patients

AGE	NUMBER
20-30	365
31-40	774
41-50	475
51-60	238
61-70	41
71-80	05
<b>Total</b>	<b>1898</b>

Category I lesion was most prevalent in age group 31-40 yrs.

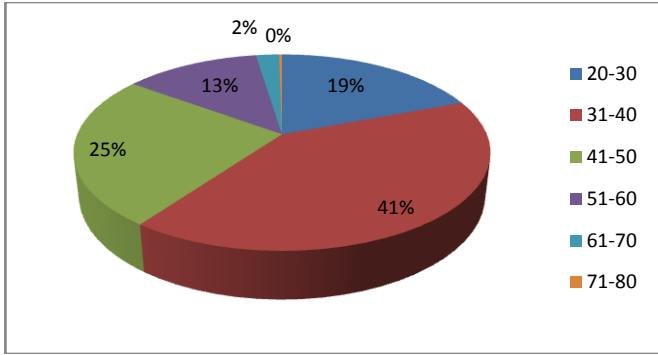


Figure 7: Age-wise distribution of category I patients

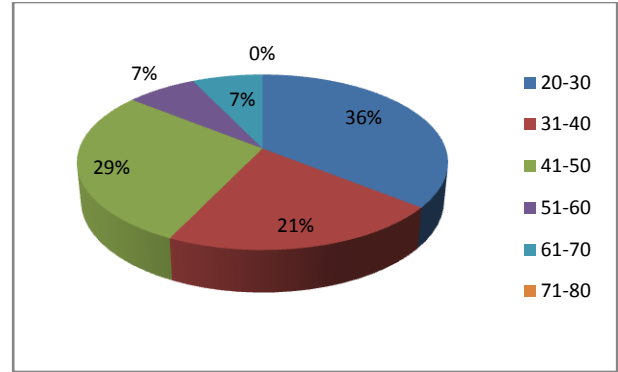


Figure 9: Age-wise distribution of category III patients

Table 6: Age-wise distribution of category II patients

AGE	NUMBER
20-30	171
31-40	246
41-50	168
51-60	43
61-70	26
71-80	04

Category II lesions was most prevalent in age group of 31-40 yrs.

Table 6: Age-wise distribution of category IV patients

Age	Number
20-30	6
31-40	26
41-50	43
51-60	32
61-70	18
71-80	02
<b>Total</b>	<b>127</b>

Category IV lesion was most prevalent in age group 41-50 yrs.

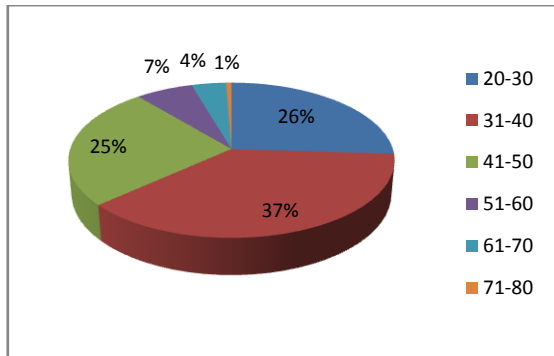


Figure 8: Age-wise distribution of category II patients

Table 5: Age-wise distribution of category III patients

Age	Number
20-30	5
31-40	3
41-50	4
51-60	1
61-70	1
71-80	0
<b>Total</b>	<b>14</b>

Category III lesion was most prevalent in age group of 20-30 yrs.

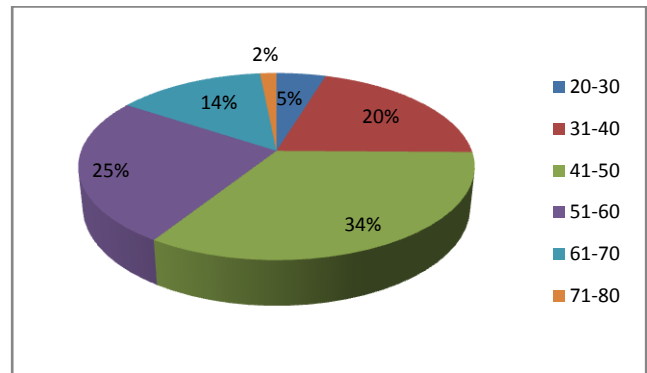


Figure 10: Age-wise distribution of category IV patients

Table 7: Age-wise distribution of category V patients

Age	Number
20-30	0
31-40	21
41-50	15
51-60	12
61-70	13
71-80	05
<b>Total</b>	<b>66</b>

Category V lesion was most prevalent in age group 31-40 and 40-50 yrs of age. BIRADS category IV and V lesions were seen in 47 patients below 40 yrs of age i.e. in 1.70 % in our patients.



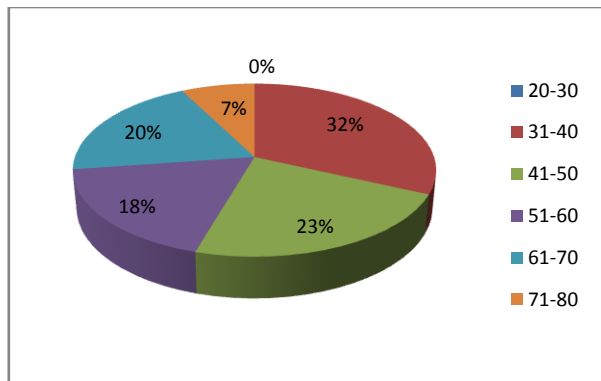


Figure 11: Age-wise distribution of category V patients

Table 8: Distribution of BI-RADS category II lesions

Age group	cystic	solid
20-30	37	134
31-40	68	178
41-50	74	94
51-60	18	25
61-70	15	11
71-80	01	03
<b>Total</b>	<b>213</b>	<b>445</b>

Solid lesions were most common than cystic lesions. BIRADS category III lesions found in 0.50 % of patients in our study and is seen in least number of patients. This percentage was less than the results obtained in the study published by Janet K. Baum. *et. al* in Radiology vol 260 number 1-july 2011.<sup>21</sup>

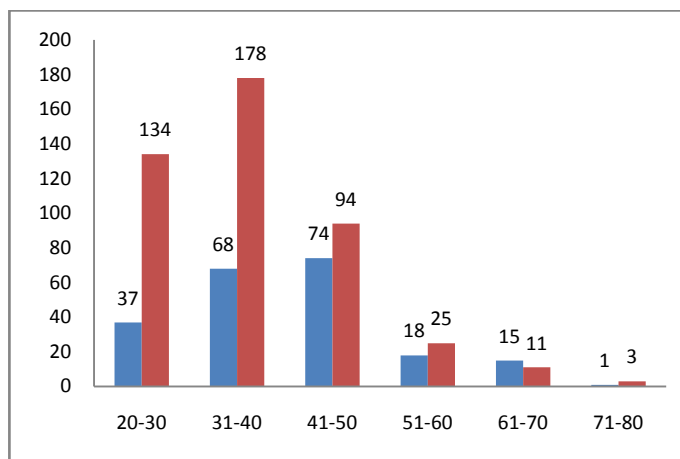


Figure 12: Distribution of BI-RADS category II lesions

Table 9: Comparison of our results with Margaret M.Eberl *et.al* study

	OUR STUDY	Margaret M.Eberl <i>et.al</i> study
I	68.69%	80.65%
II	23.81%	10.46%
III	00.50%	7.10%
IV	04.59%	1.63%
V	02.38%	0.16%

BIRADS category IV and V lesions were found in 4.59 % and 2.38 % of patients respectively. BI-RADS category IV and V lesions were more in percentage as compared to results obtained by study done by Margaret M.Eberl *et.al*<sup>22</sup>.

BIRADS category II lesions were more in percentage in our study.

## DISCUSSION

Our results suggests that BI-RADS category I lesions which suggest normal findings are commonest in our facility. Over half of the females who had mammograms had normal findings, which will serve as very important baseline information for comparison in future reviews.<sup>23</sup> These are group of patients coming with mastalgia or fibroadenosis and are very anxious of presence of malignancy. Screening such patients with resultant normal examination brings them great relief. Traditionally, palpable solid masses have undergone biopsy.<sup>24</sup> But in case of patients with BIRADS category II lesions, definitely benign nature of lesion defers the clinician from doing biopsy of the lesion and thereby reducing the procedure related morbidity. Category II lesions which suggest benign lesions are most commonly seen in 31-40 age group. Category III patients are found in least number of patients. They were advised follow up. After follow up according to the findings regarding change in nature and size of lesion they are assigned respective category. In the lesions which are classified as BI-RADS category IV and V, further investigations are recommended so that the best clinical course will be based on pathologic criteria applied. Category IV and V lesions which suggest most likely malignant lesions were seen common in 31-40 and 40-50 years age group. These findings were similar as that found in study done by E.K BRAKOHIPA.*et.al*.<sup>25</sup> The commonest age group of malignancy was above 50 years of age while we found substantial number of cases in 31-40 yrs of age group. The incidence found in our study is according to the data recently published online by National Cancer Registry Programme which suggests changing trends in breast cancer occurrence in India with increasing number of newly diagnosed cases seen in young patients<sup>26</sup>. American cancer society found incidence of malignancy in 7% patients below age of 40 years.<sup>27</sup> We found this percentage in 1.70 % in our patients. According to guidelines of American cancer society screening mammography should start at 40 to 44 yrs of age. We found more cases in 30-40 yrs and 40-50 yrs age group. This obviates the need to screen young females for breast malignancy.

## CONCLUSION

By performing mammography evaluation important baseline information about normal findings in case of BIRADS category I was given in 68.69 % of patients. It was found to be commonest category. Use of mammography and Proper classification of the lesions according to BIRADS mammography lexicon helped the clinician to avoid biopsy and thereby reduce the procedure related morbidity in total 92.5 % of patients. Category I and II mammograms found to be great relief for the patients with breast symptoms and helped to reduce anxiety regarding malignancy. Category II lesions are most commonly seen in 31-40 years age group. We found potentially malignant lesions in 31-40 and 41-50 years age group. This was according to the recent trend of occurrence of newly diagnosed cases of malignancies in younger patients. Targeted screening mammography and other investigations are hence recommended in this age group

## REFERENCES

1. SUSAN KLEIN, M.D., Southern Illinois University School of Medicine, Decatur, Illinois, Evaluation of Palpable Breast Masses, May 1, 2005 Volume 71, Number 9 [www.aafp.org/afp](http://www.aafp.org/afp) American Family Physician 1]
2. Constance D. Lehman<sup>1</sup>, Amie Y. Lee, Christoph I. Lee, Imaging Management of Palpable Breast Abnormalities, *AJR*; 203, November 2014.
3. [Emine Devolli-Disha<sup>1\*</sup>, Suzana Manxhuka-Kërliu<sup>2</sup>, Halit Ymeri<sup>1</sup>, Arben Kutllovci, comparative accuracy of mammography and ultrasound in women with breast symptoms according to age and breast density, *BOSNIAN JOURNAL OF BASIC MEDICAL SCIENCES* 2009; 9 (2): 131-136]
4. [GHEONEA IOANA ANDREEA(1), RALUCA PEGZA(2), LUANA LASCU(3), SIMONA BONDARI(1), ZOIA STOICA(1), A. BONDARI, The Role of Imaging Techniques in Diagnosis of Breast Cancer, *Current Health Sciences Journal* Vol. 37, No. 2, 2011]
5. [Expert Panel on Breast Imaging: Linda Moy, MD<sup>1</sup> ; Samantha L. Heller, MD, PhD<sup>2</sup> ; Lisa Bailey, MD<sup>3</sup> ; Carl D'Orsi, MD<sup>4</sup> ; Roberta M. DiFlorio, MD<sup>5</sup> ; Edward D. Green, MD<sup>6</sup> ; Anna I. Holbrook, MD<sup>7</sup> ; Su-Ju Lee, MD<sup>8</sup> ; Ana P. Lourenco, MD<sup>9</sup> ;
6. Martha B. Mainiero, MD<sup>10</sup>; Karla A. Sepulveda, MD<sup>11</sup>; Priscilla J. Slanetz, MD, MPH<sup>12</sup>; Sunita Trikha, MD<sup>13</sup>; Monica M. Yepes, MD<sup>14</sup>; Mary S. Newell, MD.<sup>15</sup>, PALPABLE BREAST MASSES, American College of Radiology ACR Appropriateness Criteria® Palpable Breast Masses.]
7. [Nehmat Houssami<sup>1-3</sup> Les Irwig<sup>2</sup> Judy M. Simpson<sup>2</sup> Merran McKessar<sup>1,4</sup> Steven Blome<sup>1,5</sup> Jennie Noakes<sup>4</sup>, Sydney Breast Imaging Accuracy Study: Comparative Sensitivity and Specificity of Mammography and Sonography in Young Women with Symptoms, *AJR* 2003;180:935-940]
8. Bellantone R, Rossi S, Lombardi CP, et al. Nonpalpable lesions of the breast. Diagnostic and therapeutic considerations. *Minerva Chir* 1994;49:327-333]
9. Sachin Prasad N\*, Dana Houserkova, a comparison of mammography and ultrasonography in the evaluation of breast masses, *Biomed Pap Med Fac Univ Palacky Olomouc Czech Repub.* 2007, 151(2):315-322]
10. Elizabeth S. Burnside, MD, MPH, MSa, Edward A. Sickles, MD, Lawrence W. Bassett, MD, Daniel L. Rubin, MD, MSd, Carol H. Lee, MDe, Debra M. Ikeda, MDd, Ellen B. Mendelson, MDf, Pamela A. Wilcoxg, Priscilla F. Butlery, and Carl J. D'Orsi, MDh, The ACR BI-RADS® Experience: Learning From History, *J Am Coll Radiol.* 2009 December ; 6(12): 851-860. doi:10.1016/j.jacr.2009.07.023. ]
11. [11,12,13,14,17,18,19,20] D'Orsi CJ, Bassett LW, Berg WA, et al. Breast Imaging Reporting and Data System (BI-RADS). 5th ed. Reston, Va : American College of Radiology, 2013. [15, 22] Margaret M., MPH, Chester H. Fox, MD, Stephen B. Edge, MD, Cathleen A.
12. Carter, PhD, and Martin C. Mahoney, MD, PhD, FFAFP BI-RADS Classification for Management of Abnormal Mammograms doi: 10.3122/jabfm.19.2.161-164]
13. Elizabeth S. Burnside, MD, MPH, MSa, Edward A. Sickles, MD, Lawrence W. Bassett, MD, Daniel L. Rubin, MD, MSd, Carol H. Lee, MDe, Debra M. Ikeda, MDd, Ellen B. Mendelson, MDf, Pamela A. Wilcoxg, Priscilla F. Butlery, and Carl J. D'Orsi, MDh, The ACR BI-RADS® Experience: Learning From History, *J Am Coll Radiol.* 2009 December ; 6(12): 851-860. doi:10.1016/j.jacr.2009.07.023.
14. Janet K. Baum, MD Lucy G. Hanna, MS Suddhasatta Acharyya, PhD Mary C. Mahoney, MDE Emily F. Conant, MD Lawrence W. Bassett, MD Etta D. Pisano, MD AL Use of BI-RADS 3-Probably Benign Category in the American College of Radiology Imaging Network Digital
15. Mammographic Imaging Screening Trial. *Radiology*: Volume 260: Number 1—July 2011; Volume 260:61-67] [23,25] E.K. BRAKOHIAPIA<sup>1</sup>, G.E. ARMAH<sup>2</sup>, J.N.A CLEGG-LAMPTEY<sup>3</sup> and w.o. brakohiapa<sup>4</sup>, pattern of breast diseases in accra: review of mammography reports, *ghana medical journal*, Volume 47, Number 3
16. Catherine S. Giess, MD, Lisa Zorn Smeglin, MD, Jack E. Meyer, MD, Julie
17. A. Ritner, MD, Robyn L. Birdwell, MD, Risk of Malignancy in Palpable Solid Breast Masses Considered Probable Benign or Low Suspicion, ©2012 by the American Institute of Ultrasound in Medicine *J Ultrasound Med* 2012; 31:1943-1949 0278-4297 |www.aium.org
18. web reference <http://www.breastcancerindia.net/statistics/trends.html>
19. article 18: Carey K. Andersa, Rebecca Johnsonb, Jennifer Littonc, Marianne Phillipsd, and Archie Bleyer, Breast Cancer Before Age 40 Years, *Semin Oncol.* Author manuscript; available in PMC 2010 June 29.

Source of Support: None Declared  
Conflict of Interest: None Declared