

Evaluation of portal vein anatomy and variations in a south Indian population group on routine abdominal multi-detector computed tomography

Thomas B^{1*}, Basti Ram S², Xavier Joseph V³, Kumbar Vishwanath G⁴

^{1,4}Junior Resident, ²Assistant Professor, ³Senior Resident, Department of Radio diagnosis, Father Muller Medical College, Mangalore, INDIA.
Email: dr.binstonthomas@gmail.com

Abstract

Introduction: The portal venous system is associated with a wide range of congenital variations and its preoperative detection is imperative for hepatobiliary surgical and percutaneous procedures. **Aims:** The purpose of this study is to study the normal anatomy and to determine the incidence of the types of variations and clinical implications of intrahepatic portal vein anatomy detected on routine MDCT multiphase scan of abdomen among Indian adults. **Methods and Material:** This is a retrospective study done on 200 patients who underwent MDCT of the abdomen, at our institution, for various indications. All scans were done using GE Bright speed 16 –slice MDCT, according to standard abdominal multiphase CT protocols. Main PV variations and right portal vein variations were investigated as 5 separate groups. All cases were assessed by a single radiologist, for the existence of, type, and number of PV variations. **Results:** In our study of 200 patients, with almost equal sex distribution (males 103/ 200 and females 97 /200), the standard portal venous anatomy was seen in 81.5% and the prevalence of portal vein variation was 18.5 %. Type 2 accounted for (23 /200) 11.5% and was the most common variant followed by type 3 (9 /200) 4.5%. The prevalence of right portal vein variations in our study was 2.5 percent. No significant association was seen between sex distribution and the presence of portal vein variations. **Conclusions:** Radiologist and surgeons need to be aware of portal vein variations, especially in cases pertaining to liver interventions. Our study shows a relatively smaller incidence of portal vein variation in the Indian study group compared to that of recent literature. However a study on a larger group is imperative to unravel the true extent of portal vein variations in the Indian population. **Keywords:** portal vein, portal vein variations, right portal vein branch variations, preoperative imaging, clinical significance, Multi detector computed tomography.

*Address for Correspondence:

Dr. Binston Thomas, Resident, Department of Radio - Diagnosis, Father Muller Medical College, Mangalore - 575002, INDIA.

Email: dr.binstonthomas@gmail.com

Received Date: 27/08/2018 Accepted Date: 07/10/2018

Access this article online	
Quick Response Code:	Website: www.statperson.com
	Volume 8 Issue 4

INTRODUCTION

Intrahepatic portal vein anatomy was first described many years ago on cadaveric liver dissection and with corrosion casts of explanted liver. Modern imaging techniques such as multislice computed tomography (CT) and magnetic

resonance imaging (MRI) however has greatly influenced the study of vascular anatomy in the current day practice.¹ The portal venous system is associated with a wide range of congenital variations. With the advent and progress of hepatobiliary surgical and percutaneous procedures, including trisegmentectomy, portal vein embolization, and transjugular intrahepatic portosystemic shunts (TIPS), to name a few, the detection and recognition of portal vein variants have become of critical importance.² Portal vein variations have recently been associated with biliary hilar variations as well.³ Three-dimensional (3D) imaging has been made possible with improvements in Multidetector computed tomography (MDCT) systems, along with developments in computer and imaging techniques.^{4,5} 3D imaging techniques, such as maximum intensity projection (MIP), multiplanar reconstruction (MPR), and volume rendering (VR), enable detailed

imaging of venous structures with MDCT. Routine liver MDCT examinations demonstrate Portal vein (PV) variations simultaneously.⁶ Though, studies investigating PV variations with MDCT have been previously reported, there are only few studies investigating its prevalence among Indians. The aim of this study is to determine the types, prevalence rates, and clinical implications of PV variations in routine abdominal MDCT examinations among a sample of adult south Indian patient group.

OBJECTIVE

The purpose of this study was to study the normal anatomy and to determine the incidence of the types of variations and clinical implications of intrahepatic portal vein anatomy detected on routine MDCT multiphase scan of abdomen among Indian adults.

METHODS

Patients

A total of 200 patients, who underwent MDCT of the abdomen, at our institution, for various indications were included in our study. Data was obtained retrospectively from July 2013 to October 2013. Patients with gross abnormalities of the liver, distorting the vascular anatomy were excluded.

Image acquisition and processing

All scans were done using GE Bright speed 16 –slice MDCT with 120 KVp and 300 mAs with 5mm slice thickness, 0.8 second gantry rotation. Scanning protocol consisted of unenhanced and biphasic contrast enhanced scans. 70-80 ml of 350mg/ml non ionic iodinated contrast was injected using automated injector at the rate of 3-4ml/second. Start delay of 30 seconds was given for arterial phase and 70-80 seconds for portal venous phase and imaged from the diaphragm to the pubic symphysis level. Images were retro reconstructed with 0.625 mm slice thickness and reformatted in sagittal and coronal planes for analysis.

Interpretation

Main PV variations, right PV variations, were investigated as 5 separate groups.⁽²⁾ The main PV that branches into a large right PV and a smaller left PV at the level of the liver hilus in normal (standard) anatomy was classified as type 1. The left PV lies horizontally, medial to the ligamentum teres. The main component supplies segments II and III of the liver, superior and inferior branches supply segment IV, and caudate branches supply segment I. The right PV branches into the anterior (right APV) truncus and the posterior (right PPV) truncus. Branches of the anterior truncus supply segments V and VIII, and branches of the posterior truncus supply segments VI and VII. (Fig 2A) Any configuration other than these was considered anatomic variation.

Trifurcation of the main PV into the left PV, right APV, and right PPV was considered type 2 branching pattern (Fig 2B), while branching of the right PPV from the main PV as the first and separate branch was considered type 3 (Fig 2C). Configuration of the gap between origins of the right APV and right PPV was used for discrimination of type 2 and type 3 PV. ⁽⁷⁾ If this configuration was triangular, type 2 was diagnosed; if rectangular, type 3 was diagnosed. ⁽⁷⁾ Two common right portal vein branch variations were also considered in the study and were classified into type 4 i.e., segment VII branch arising separately from the right portal vein and type 5 i.e., segment VI branch arising separately from the right portal vein (Fig 2D). A category of others was created to include any other rare variations. The initial axial images and the processed images using maximum intensity projection (MIP) and multiplanar reconstruction (MPR) images were used for assessment. All cases were assessed by a single radiologist, for the existence of, type, and number of PV variations. Consultation was sought with a second radiologist in complex cases.

RESULTS

Our study group comprised 200 patients. The mean age of patients was 53.5yrs. The sex distribution in our study was almost equal, males 103/ 200 and females 97 /200. The standard portal venous anatomy (type 1) was seen in 81.5%. The prevalence of portal vein variations was 18.5 %. Type 2 accounted for (23 /200) 11.5% and was the most common variant followed by type 3 (9 /200) in 4.5% patients. Of the 37 cases of variations, type 2 accounted for 62%, type 3 accounted for 24 %, type 4 were nil, type 5 accounted for 10.8% and one isolated case of right portal vein with no branch was observed. The prevalence of right portal vein variations in our study was 2.5 percent. No significance was seen between sex distribution and the presence of portal vein variation (p > 0.05). There were no left portal vein variations in this study.

Table 1: Anatomic variation in portal vein anatomy

Type	Portal vein variant	No of patients	percentage
1	Standard anatomy	163	81.5
2	Trifurcation	23	11.5
3	Right PPV, first branch of main PV	9	4.5
4	Segment VII branch as separate branch of right PV	0	0
5	Segment VI branch as separate branch of right PV	4	2.0
Others	No division of right branch of portal vein	1	0.5
Total		200	100.0

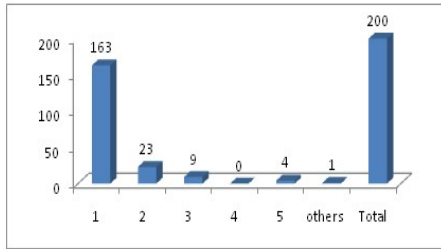


Figure 1: Distribution of anatomic variation of portal vein

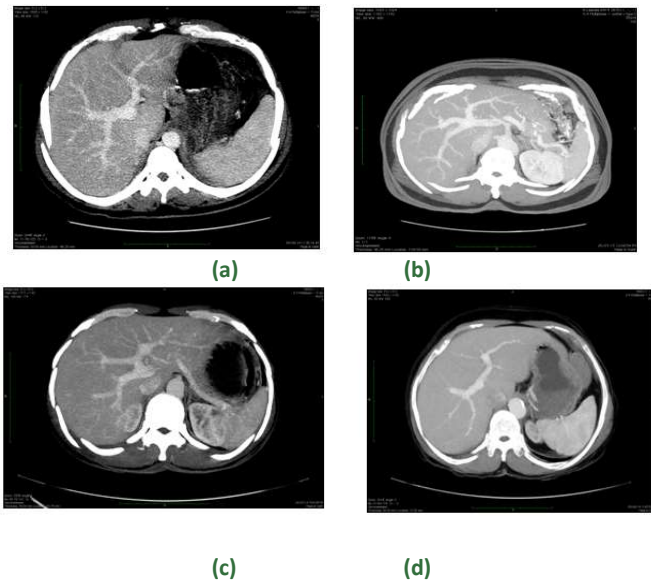


Figure 2: A–D, Post contrast MIP images depict standard portal vein anatomy (type 1, A), trifurcation (type 2, B), right posterior portal vein as first branch of main portal vein (type 3, C), segment VI branch as separate branch of right portal vein (types 5, D).

DISCUSSION

Embryologically, the portal vein is formed in the second month of gestation by selective involution of the vitelline veins, which have multiple bridging anastomoses anterior and posterior to the duodenum. Alterations in the pattern of obliteration of these anastomoses can result in several variants.^{2, 8} In the conventional anatomy the portal vein originates from the confluence of the superior mesenteric, inferior mesenteric, and splenic veins posterior to the neck of the pancreas. In its most common branching pattern, the portal vein divides at the porta hepatis into the right and left portal veins. As it courses cranially, the right portal vein first sends branches to the caudate lobe and then divides into anterior and posterior branches. The left portal vein first follows a horizontal course to the left and then turns medially toward the ligamentum teres (umbilical portion), supplying the lateral and medial segments of the left lobe.⁹ Besides the three types of main portal vein variations and two types of right branch variation discussed in our study there are few other rare variations of the main portal vein like quadrification in

which the portal vein divides into a left portal branch and three separate right portal branches and a more complex variant, the so-called “absence of portal vein bifurcation”, and the so called “fusion of the central plane of the liver.” An uncommon right portal vein variation concerns the origin of the segment V branch, originating from the right posterior portal vein or directly from the right portal vein.¹ In our study of 200 patients, with almost equal sex distribution (males 103/ 200 and females 97 /200), the standard portal venous anatomy was seen in 81.5% and the prevalence of portal vein variation was 18.5 %. Type 2 accounted for (23 /200) 11.5% and was the most common variant followed by type 3 (9 /200) 4.5%. Of the 37 cases of variation, type 2 accounted for 62%, type 3 for 24 %, type 4 were nil, type 5 for 10.8% and one isolated case of right portal vein with no branch. The prevalence of right portal vein variations in our study was 2.5 percent. No significance was seen between sex distribution and the presence of portal vein variations. Zafer koc *et al*⁷ studied 1396 patients and showed that the prevalence of PV variations was as high as 27.4%. The rate of main PV branching variation was 21.5%, right PV variation was 3.9%, and segmental PV origin traversing the interlobar boundary was 4%. The most common main PV variations were trifurcation (11.1%) and the right posterior PV branch being the first branch of the main PV (9.7%) similar to our study. Interpretation and determination of the prevalence of rare PV variations were possible as a result of a large study sample. A statistically significant difference in the prevalences of PV variations was not detected between male and female patients ($P = 0.582$) just as in our study. Anne *et al*² in a study of 200 patients showed a prevalence of 35% in variant portal vein anatomy which was higher than that of our study. In their cohort, 22% patients had either trifurcation (type 2) or ‘Z’ type (type 3) anatomy. Fourteen patients (7%) had what we considered a single posterior segment branch (types 4 and 5) arising as the first branch of the right portal vein. The percentages of the sub variants were also lower in our study. However the most common variant was trifurcation just as in our study. Cheng *et al*¹⁰ who studied 200 patients found that 65% of those who underwent conventional arteriportography had standard portal vein anatomy. This study too showed and higher prevalence of variant anatomy compared to our study. Their study was limited by conventional arteriportography’s ability to accurately determine segmental branching patterns. Carr *et al*¹¹ studied 24 patients who underwent pretransplantation MR angiography to delineate hepatic vasculature; conventional portal vein anatomy was seen in 76%. Four patients (16%) had trifurcation and an additional two (8%) had Z type anatomy (type 3). This study showed

results closer to our study. However, the study did not identify cases with other variants like the right branch variants which accounted for 2.5% of our cases. Cetin et al¹² in a study of total 200 patients, showed 131 (65.5%) had conventional portal venous anatomy (type 1). Nineteen (9.5%) of the patients had trifurcation (type 2), and 47 (23.5%) had type 3 anatomy and 22 (16.8%) of these patients had variant RPV branching. This study too showed a higher prevalence than our study. In this study type 3 was however found to be the commoner variant. The knowledge of portal vein variants is gaining significance in modern medicine especially, in transplant surgery and percutaneous interventional procedures. In surgery, if the segment VI or VII portal vein arises alone as the first branch of the main portal vein, a left trisegmentectomy may inadvertently leave a single viable liver segment as the entire remnant liver, potentially resulting in liver failure and death. Failure to recognize a Z type portal vein variant (type 3) during a left liver resection or when harvesting a living donor liver transplant may result in loss of perfusion to the right anterior sector and compromise the remnant liver. Trifurcation of the portal vein may require two separate anastomoses when the right liver is transplanted to an adult donor. Transhepatic portal vein embolization is now being accepted as a method to induce contralateral liver hypertrophy in patients with small future remnant livers. Embolizing a nontargeted sector or segment in this patient population can make potentially respectable anatomy unrespectable. TIPS are another interventional procedure in which portal vein anatomy may be relevant. TIPS placement often depends on the blind canalization of the portal vein by a puncture originating from the hepatic vein. In standard anatomy, the portal vein lies in a predictable position to the hepatic vein, accounting for high success rates. In portal vein trifurcation the portal vein puncture site created during a TIPS placement can be acute and therefore difficult to stent. In other cases, variant portal vein anatomy may not allow successful access using a standard approach. Hence, cross-sectional imaging is soon becoming the standard of care in the preprocedural and presurgical planning.^{1,2}

CONCLUSIONS

In conclusion, radiologist and surgeons need to be aware of portal vein variations, especially in cases pertaining to

liver interventions. Our study shows a relatively smaller incidence of portal vein variation in the Indian study group compared to that of recent literature. However a study on a larger group is imperative to unravel the true extent of portal vein variations in the Indian population.

REFERENCE

- Schmidt S, Demartines N, Soler N, Schnyder P *et al.* Portal vein normal anatomy and variants: Implication for liver surgery and portal Vein embolization. *Semin Intervent Radiol* 2008; 25:86–91.
- Covey A M, Lynn A, George B *et al.* Incidence, Patterns, and Clinical Relevance of Variant Portal Vein Anatomy. *AJR* 2004; 183: 1055-1064.
- Kitami M, Takase K, Murakami G, *et al.* Types and frequencies of biliary tract variations associated with a major portal venous anomaly: analysis with multi-detector row CT cholangiography. *Radiology* 2006; 238(1):156–166.
- Kamel IR, Kruskal JB. Living donor liver transplantation in adults: vascular variants important in surgical planning for donors and recipients. *AJR Am J Roentgenol* 2003; 181:109–114.
- Calhoun PS, Kuszyk BS, Heath DG, Carley JC, Fishman EK. Three-dimensional volume rendering of spiral CT data: theory and method. *Radiographics* 1999; 19:745–764.
- Fishman EK. CT angiography: clinical applications in the abdomen. *Radiographics* 2001; 21:3–16.
- Koc Z, Oğuzkurt L, Uluhan S. Portal vein variations: clinical implications and frequencies in routine abdominal Multidetector CT. *Diagn Interv Radiol* 2007; 13:75-80.
- Walsh G, Williams MP. Congenital anomalies of the portal venous system: CT appearances with embryological considerations. *Clin Radiol* 1995; 50:174–176.
- Özbülül N I. Congenital and acquired abnormalities of the portal venous system: multidetector CT appearances. *Diagn Interv Radiol* 2011; 17:135–142.
- Cheng YF, Huang TL, Chen CL, *et al.* Anatomic dissociation between the intrahepatic bile duct and portal vein: risk factors for left hepatectomy. *World J Surg* 1997; 21:297–300.
- Carr JC, Nemcek AA Jr, Abecassis M, *et al.* Preoperative evaluation of the entire hepatic vasculature in living liver donors with the use of contrast-enhanced MR angiography and true fast imaging with steady-state precession. *J Vasc Interv Radiol* 2003; 14:441–449.
- Atasoy C, Özyürek E. Prevalence and Types of Main and Right Portal Vein Branching Variations on MDCT. *AJR* 2006; 187:676–681.

Source of Support: None Declared
Conflict of Interest: None Declared