

Variant arterial pattern in upper limb with persistent median artery

A D Kannamwar^{1*}, G L Maske², I V Ingole³

^{1,2}Assistant Professor, Department of Anatomy, Shri V. N. Government Medical College, Yavatmal, Maharashtra, INDIA.

³Professor, Department of Anatomy, PDMC, Amravati, Maharashtra, INDIA.

Email: drarchanamaske@gmail.com, gajananlmaske@rediffmail.com

Abstract

During routine dissection classes we observed bilateral anatomical variations of the brachial and ante brachial arterial pattern and along with variant superficial palmar arch formation. We will be reporting this case with its embryological correlation and clinical implications.

Keywords: Bilateral variations, Brachial Artery, Antebrachial arterial pattern, Superficial palmar arch.

*Address for Correspondence:

Dr. A D Kannamwar, Assistant Professor, Department of Anatomy, Shri V. N. government medical college, Yavatmal, Maharashtra, INDIA.

Email: drarchanamaske@gmail.com

Received Date: 25/02/2019 Accepted Date: 07/04/2019

Access this article online

Quick Response Code:



Website:

www.statperson.com

Volume 9
Issue 2

INTRODUCTION

Variations in number and / or course of the Brachial and Antebrachial arteries have clinical and surgical significance. Variations in the arterial pattern of the upper limb have been observed frequently, either in routine dissections or in clinical practice. Anatomy textbooks make reference to 'Vas aberrans' in the main brachio-antebrachial arterial pattern which are the departures from anatomical norm, with respect to origin course & branching pattern of the arteries of the upper extremities.¹

These are grouped into four categories:

- related to radial artery
- related to ulnar artery
- related to brachial arterial pattern
- the presence of accessory brachial artery

These variations and anomalies of the arterial supply to the upper limb can best be explained on the basis of the development of vascular plexuses of the limb buds.

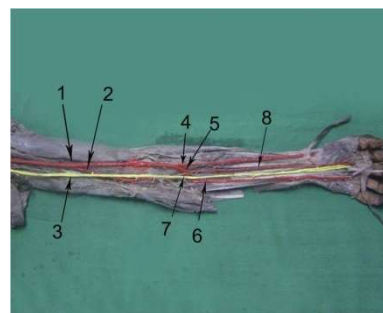
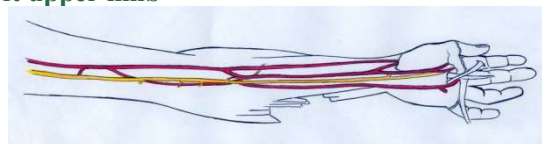
MATERIALS AND METHOD:

Conventional dissection technique.

OBSERVATION AND RESULTS

During routine dissection classes we observed bilateral anatomical variations of the brachial and ante brachial arterial pattern & superficial palmar arch formation which were different on two sides, in the middle aged male cadaver.

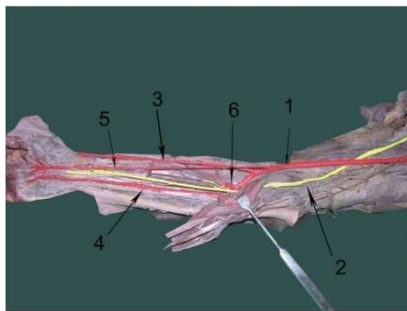
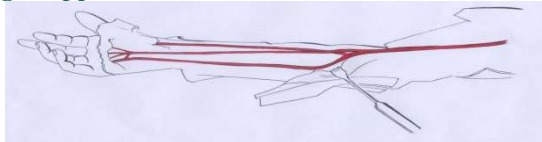
a) left upper limb



Photograph no. 1 & this sketch is showing arterial pattern in left upper limb in which we can see single vessel dividing into two branches in the middle of the arm labeled 1 & 2. 2 lying deep to median nerve. We cannot say which was the main brachial artery is & which is the accessory one, as both of these vessels are terminating by

dividing into two branches each. Out of these branches, branch on radial side (4) takes course of radial artery while branch on ulnar side (6) takes course of ulnar artery. Branches in the middle (5 & 7) anastomoses with each other & give rise to interosseous complex along with a median artery (8) which accompany median nerve & can be labeled as Arteria nervi mediana. We also observed that the superficial palmar arch was completed by this median artery on radial side which is usually completed by superficial branch of radial artery.

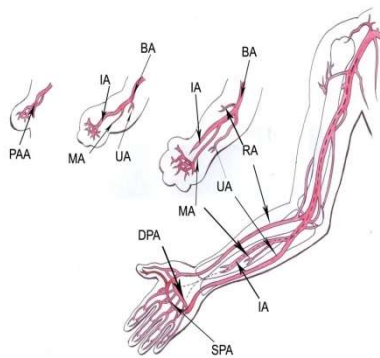
b) right upper limb



Photograph no. 2 & this sketch is of right hand of same cadaver, showing a single brachial artery which is running superficial to median nerve so can be called as superficial brachial artery. It is giving one unusual branch from its anterior side in the lower part of the arm which then continues as median artery which also completed the superficial palmar arch in palm like that in left upper limb.

DISCUSSIONS

Embryogenesis of Vascular Pattern of Human Upper Limb^{2,3}



- Variations may result from persistence of channels that would normally be obliterated or from a choice of unusual paths in the primitive vascular plexus.
- Hemodynamic factors
- Genetic factors
- Limb position^{4, 5, 6}

Clinical Implications

- i. Accidental intra arterial injection
- ii. Hazards in reparative or vascular surgeries in arm, forearm and hand
- iii. Alternate channel of blood supply in case of occlusion
- iv. More vulnerable to trauma but more accessible to cannulation.
- v. Disturb evaluation of angiographic images

CONCLUSION

Variation in branching pattern of main brachial and ante brachial artery are frequently observed because of their developmental factors. But these types of bilateral variations are of rare occurrence. Their knowledge is of utmost importance for clinicians, surgeons and radiologists as ignorance may lead to many life threatening complications in patients.

REFERENCES

1. Hollinshed Henry. (1962) Anatomy for Surgeons-Back and limbs Vol 3 In: Arm,elbow & forearm And The Wrist & hand. 2nd edition. Harper & Row publishers:pp 368-373, 411-417, 490-498.
2. Moore K.L. & Persaud T.V.N. (2004) The developing human-Clinically oriented embryology; Limbs: Blood supply of limbs. 7th edition. Saunders An imprint of Elsevier. Pp:412-425
3. Patten B.M. (1953) Human embryology : Development of circulatory system: Arteries of extremities. 2nd edition. McGraw-Hill Book Company INC. pp 632-637.
4. R. A. Fadel and H. S. Amonoo-Kuofi (1996) The superficial Ulnar artery: Development and surgical significance. Clinical Anatomy 9:128-132
5. A. Rodriguez-Baeza, J. Nebot, B.Ferreira, F.Reina, J. Perez, J.R. Sanudo And M.Roig (1995) An anatomical study and ontogenic explanation of 23 cases with variations in the main pattern of the human brachio-antebrachial arteries. J.Anat 187, pp. 473-479.
6. Patnaik, V.V.G;Kalsey, G.Singla Rajan K. (2002) Branching Pattern of Brachial artery-A Morphological Study. J.Anat. Soc. India 51(2) 176-186.

Source of Support: None Declared
Conflict of Interest: None Declared