

# Variation in the origin of lateral circumflex femoral artery

Asharani S K<sup>1\*</sup>, Vasantha Kuberappa<sup>2</sup>, Divyalatha<sup>3</sup>

<sup>1</sup>Assistant Professor, <sup>3</sup>Lecturer, Department of Anatomy, Adichunchanagiri Institute of Medical Sciences, B G Nagar Nagamangala, Mandya (district) – 571448, Karnataka, INDIA.

<sup>2</sup>Assistant Professor, Department of Anatomy, Karwar Institute of Medical Sciences, Karnataka, INDIA.

Email: [ashakshetty@gmail.com](mailto:ashakshetty@gmail.com)

## Abstract

**Introduction:** The lateral circumflex femoral artery arises from the lateral side of the profundafemoris artery, passes horizontally between the divisions of the femoral nerve and behind the Sartorius and rectus femoris, and divides into ascending, transverse and descending branches. During routine dissection of cadavers allotted for first MBBS students, variation in the origin of lateral circumflex femoral artery was observed unilaterally in an old aged female cadaver. In the present study, the lateral circumflex femoral artery was taking origin directly from the lateral side of femoral artery. The branches of lateral circumflex femoral artery are used in making anterolateral thigh flap for reconstruction of defects in face, aorto-popliteal bypass, coronary artery bypass grafting. As the femoral artery is the main artery of the lower limb and is frequently visualized by various radiological imaging techniques, anatomical variations of itself as well as its branches have significant clinical importance.

**Keywords:** Femoral artery, Femoral nerve, Lateral circumflex femoral artery, Profundafemoris artery.

## \*Address for Correspondence:

Dr. Asharani S. K., Assistant Professor, Department of Anatomy, Adichunchanagiri Institute of Medical Sciences, B G Nagar Nagamangala, Mandya (district) – 571448, Karnataka, INDIA.

Email: [ashakshetty@gmail.com](mailto:ashakshetty@gmail.com)

Received Date: 15/01/2019 Accepted Date: 01/04/2019

| Access this article online  |  |
|---|--|
| Quick Response Code:  | Website:<br><a href="http://www.statperson.com">www.statperson.com</a> |
|  | Volume 9<br>Issue 2  |

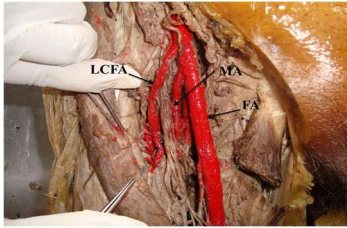
supplies the anterolateral thigh fasciocutaneous flap, which is based on the fasciocutaneous perforators that arise from the descending branch<sup>1</sup>. Variations which involve the Femoral, Profundafemoris and lateral circumflex femoral arteries are important in vascular reconstructive surgeries, in surgical interventions for embolism, and in raising myocutaneous grafts with pedicles<sup>2</sup>. Since femoral artery is easily accessible, peripheral arteriograms and catheterization have become easy now a day to evaluate peripheral occlusive arterial diseases. Therefore variations of itself as well as its branches have significant clinical importance.

## INTRODUCTION

Variations have been described for almost every artery of the human body each one having more or less clinical significance. The lateral circumflex femoral artery is a laterally running branch given off near the root of the profunda. It passes between the divisions of the femoral nerve, posterior to sartorius and rectus femoris and divides into ascending, transverse and descending branches. It supplies head and neck of femur, greater trochanter, vastuslateralis and knee. The ascending branch forms the pedicle of the tensor fasciae lataemusculocutaneous flap. The descending branch

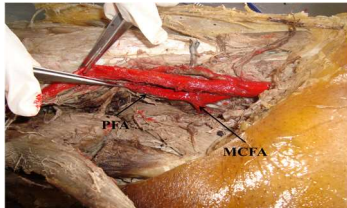
## CASE REPORT

During routine dissection of female cadaver in the department of anatomy, variation in the origin of lateral circumflex femoral artery was observed. It was directly taking origin from the lateral side of right femoral artery and passing between the two divisions of femoral nerve. On the left side lateral circumflex femoral artery was taking origin from profundafemoris artery.



**Figure 1:** Showing the Variant origin of right lateral circumflex femoral artery

FA-femoral artery, FN-femoral nerve, LCFA- lateral circumflex femoral artery



**Figure 2:** Showing the normal origin of right medial circumflex femoral artery, MCFA-medial circumflex femoral artery, PFA-profunda femoris artery

## DISCUSSION

The arteries of the lower limb develop from the axis artery, which is derived from the fifth lumbar artery. In the developmental process, some of the channels regress and some of them enlarge and form a definitive arterial pattern. The persistence of the channels that are supposed to disappear, lead to various vascular anomalies which may complicate arteriectomies, embolectomies and thromboendarterectomies in cases of atherosclerosis, which are most commonly seen in the lower limb vessels<sup>3</sup>.

The anomalous patterns of lateral circumflex femoral artery may be due to

1. Divergence in the mode and proximodistal level of branching.
2. Presence of unusual compound arterial segments.
3. Aberrant vessels that connect with principal vessels, arcades or plexuses
4. Vessels that occupy exceptional tissue planes (e.g. superficial fascia instead of sub fascia).
5. Have unsuspected neural mycological or osteoligamentous relationships<sup>4</sup>.

In the present scenario, peripheral nerve blockade offers many advantages for patients undergoing orthopaedic surgery of the lower extremity. Therefore the knowledge of variation of this artery is important for anaesthetics during femoral nerve blockade and also during clinical procedures in the femoral region and hip joint replacements. In a study done by Steven L. Orebaugh, lateral circumflex femoral artery was arising directly from femoral artery in 10-20% of specimens<sup>5</sup>.

Hollinshead reports that the lateral circumflex femoral artery arises from the femoral artery in 15% of cases proximal to the Profundafemoris artery<sup>6</sup>. Vazquez *et al.* classified the medial and lateral circumflex femoral arteries into three different patterns based on the levels of their origin. Distribution related to sex and side has also been studied. Pattern I: Both arteries arise from the Profundafemoris artery (78.8%). This pattern is more frequent in females. Type Ia, Medial circumflex femoral artery origin is proximal to the origin of lateral circumflex femoral artery (53.2%); Type Ib, Lateral circumflex femoral artery origin is proximal to the origin of medial circumflex femoral artery (23.4%); Type Ic, both arteries arise from a common trunk (23.4%). Pattern II: One of the arteries arise from the femoral artery and the other from the profundafemoris artery (20.5%). Type IIa, the medial circumflex femoral artery arises from the femoral artery (77.8%) and Type IIb, the lateral circumflex femoral artery arises from the femoral artery (22.2%). Pattern III: Both arteries arise from the femoral artery (0.5%)<sup>7</sup>. The present case comes under type IIb. A study done by Havaldar PP *et al.* on 50 specimens shows the origin of lateral circumflex femoral artery from profundafemoris in 45 specimens and from femoral artery in 5 specimens<sup>2</sup>. Uzel *et al.* in a study of 110 inguinal regions (55 cadavers) have found that the lateral circumflex femoral artery arose from profundafemoris artery in 85 cases (77.3%), from the femoral artery in 21 cases (19.1%). They have also found a common trunk from where the profundafemoris artery and the lateral circumflex arteries were taking origin in 1 case (0.9%) and another common trunk for profundafemoris artery, medial circumflex femoral artery and lateral circumflex femoral artery in 1 case (0.9%). They have found the ascending and descending branches of the lateral circumflex artery to be arising from the femoral artery and the profundafemoris artery respectively in 2 cases (1.8%)<sup>8</sup>. Rui Fernandes and Jason Lee have reported the successful use of the lateral circumflex femoral artery perforator flap as a reliable option for the immediate reconstruction of large defects secondary to gunshot wounds of the face. The lateral circumflex femoral artery perforator flap is at a site which is not involved in the immediate resuscitation of trauma patients, thus ensuring an intact vascular system. This fact makes the lateral circumflex femoral artery perforator flap a reliable source for small to large soft tissues for reconstructing avulsive soft tissue losses in the head and neck<sup>9</sup>. The descending branch of the lateral circumflex femoral artery has been used successfully as a high flow conduit for extra cranial-intracranial bypass surgery<sup>10</sup>.

## CONCLUSION

Knowledge of variation of lateral circumflex femoral artery is important during clinical procedures within the femoral region and in hipjoint replacement<sup>7</sup>. Lateral circumflex femoral artery is used as a perforator flap in the reconstruction of gunshot wounds<sup>9</sup>. Its branches are used in making anterolateral thigh flap for reconstruction of defects in face, aorto-popliteal bypass, coronary artery bypass grafting<sup>11</sup>. The descending branch of the lateral circumflex femoral artery can be used as a high flow conduit for extracranial - intracranial bypass surgery<sup>10</sup>. Profundafemoris artery and its branches are encountered during femoral artery cannulation for various clinical and diagnostic techniques<sup>12</sup>. Therefore it is important that appreciation of vascular anatomy and variations in the femoral artery and its branches may prove useful to the surgeons, radiologists and regional anaesthetics and contribute to patient safety.

## REFERENCES

1. Gray H. Arteries of thigh. In: Standring S. Gray's Anatomy. The Anatomical basis of clinical practice. 40<sup>th</sup> edition. London: Churchill Livingstone Elsevier, 2008; 1380.
2. Havaladar PP, Myageri M, Saheb SH. Study of lateral circumflex artery. International Journal of Anatomy and Research 2014; 2(2): 397-9.
3. Anupama D, Subhash LPR, Suresh BS, Nagaraj DN. Variation in origin of the Lateral circumflex femoral artery- A case report. Research Journal of Pharmaceutical, Biological and Chemical Sciences 2013; 4(3): 818-21.
4. Balachandra N, Prakash BS, Padmalatha K, Ramesh BR. Variation in the origin of the lateral circumflex femoral artery – A case report. Anatomica Karnataka 2011; 5(1): 76-80.
5. Orebaugh SL. The femoral nerve and its relationship to the lateral circumflex femoral artery. AnesthAnalg 2006; 102: 1859-62.
6. Hollinshead WH. Text Book of Anatomy. 3rd edition, Harper and Row, 1974; 407.
7. Vazquez MT, Murillo J, Maranillo E, Parkin I, Sanudo J. Patterns of the circumflex femoral arteries revisited. ClinAnat 2007; 20(2): 180-5.
8. Uzel M, TanyeliE, Yildirim M. An anatomical study of the origins of Lateral circumflex femoral artery in the Turkish population. Folia Morphol 2008; 67(4): 226-30.
9. Fernandes R, Lee J. The use of Lateral circumflex femoral artery perforator flap in the Reconstruction of gunshot wounds of the face. Journal Oral and Maxillofacial surgery. 2007; 65(10): 1990-7.
10. Baskaya MK, Kiehn MW, Ahmed A S, Ates O, Niemann D B. Alternative vascular graft for extracranial-intracranial bypass surgery: descending branch of lateral circumflex femoral artery. Neurosurg Focus 2008; 24(2): E8.
11. Atulya, Kharb P, Samanta PP. Variation in Origin and Branching Pattern of Lateral Circumflex Femoral Artery: A Rare Case Report. International Journal of Health and Rehabilitation Sciences 2013; 2(1): 72-5.
12. Baptist M, Sultana F and Hussain T. Anatomical variation in the origin of ProfundaFemoris artery, its branches and diameter of the Femoral artery. Professional Med Journal 2007; 14(3): 523-7.

Source of Support: None Declared  
Conflict of Interest: None Declared